

## EVALUATION OF THE CLINICOPATHOLOGICAL CHARACTERISTICS OF LABIAL MUCOCELE

**Ali Darweesh AL Sarraj\* & Riad G Al-Tae#**

\*HDD, MSc, Department of oral surgery, College of Dentistry, University of Basrah, Iraq.

#FICMS, Departement of oral surgery, College of Dentistry, University of Basrah.

E-mail. [dralial\\_sarrag@yahoo.com](mailto:dralial_sarrag@yahoo.com)

### Abstract

The objective of the present study is to evaluate the clinicopathological characteristics of labial mucocele. Eighteen cases of labial mucocele were studied, a special protocol was designed and clinical & histopathological variables were recorded. Only one mucocele occurred in the upper lip, the rest being in the lower lip. One was bilateral. Of the mucoceles examined, 88% were of the extravasation type and 11% were retention. Of the 16 classified as of the retention type, 12.5% were in the initial stage, 31.25% in the resorption stage and 56.25% in the final stage. It is concluded that diagnosis can be established from clinical details although a histopathological study is necessary to confirm the diagnosis.

### Introduction

A Mucous cyst (MC) is a benign, common, mucus-containing cystic lesion of the minor salivary glands in the oral cavity. Some authors<sup>1</sup> prefer the term mucocele since most of these lesions are not true cysts in the absence of an epithelial lining. The lesions can be located directly under the mucosa (superficial mucocele), in the upper submucosa (classic mucocele), or in the lower corium (deep mucocele). Two types of MC occur based on the histologic features of the cyst wall: a mucous extravasation cyst formed by mucous pools surrounded by granulation tissue (92%) and a mucous retention cyst with an epithelial lining (8%)<sup>2,3</sup>.

Mucocele represented the 15th most common oral mucosal lesion, with a prevalence of 2.4 cases per 1000 people. Although the prevalence in children is not known, it is estimated to be higher than in adults. Studies showed a high frequency in children with association of this reactive lesion with head and neck trauma<sup>3</sup>. Mucoceles of the anterior

lingual salivary glands (glands of Blandin and Nuhn) are relatively uncommon, with only isolated case reports and case series in the literature. This type of mucocele represents an estimated 2-8% of all mucoceles. Superficial mucoceles are typically located in the soft palate, the retromolar region and the posterior buccal mucosa. They represent approximately 6% of all mucoceles. Multiple superficial mucoceles have been reported in a small number of patients<sup>4,5</sup>.

Salivary mucoceles are much more common in the lower lip, but they may also occur in other locations (the floor of the mouth, the cheek, the palate, the retromolar fossa and the dorsal surface of the tongue. These lesions spare the upper lip<sup>5</sup>. Clinically it appears as a discrete, more or less soft, fluctuant, painless swelling of the mucosa. The size varies from a few millimeters to several centimeters in diameter, but 75% of the lesions are smaller than 1 cm in diameter. In most cases, diagnosis can be

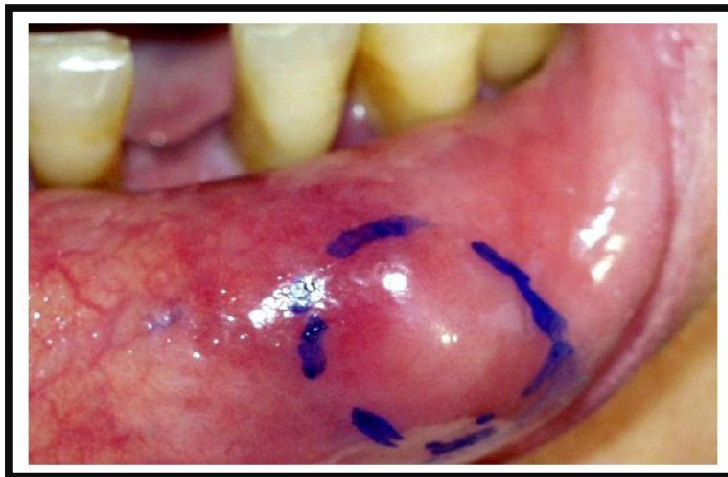established from clinical details, although a histopathological study is necessary to confirm the diagnosis<sup>6,7</sup>. The most effective treatment involves complete surgical extirpation. The objective of the present study is to evaluate the clinico-pathological characteristics of labial mucocele.

### Material & Methods

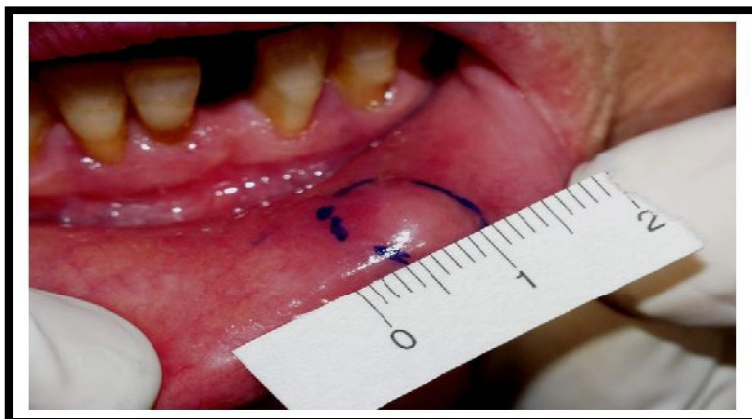
Eighteen cases of labial mucocele were studied by protocol including clinical (age when first presented, color, consistency, length of evolution and size Fig.1&2) and histopathological variables were estimated. Helsinki rules were followed and informed consent of each of the patients was obtained.

All cases involved surgical removal using the same technique. Local anesthesia around the presumed mucocele was obtained with the application of topical 20% benzocaine on a 2 X 2-inch gauze followed within several minutes by the submucosal injection of 1% lidocaine with 1:100,000 epinephrine (Normon SL, Barcelona Spain). The extirpation was done including the immediate adjacent glandular tissue. (Fig.3) After the surgical intervention, 600mg ibuprofen was prescribed to the patients after every 8 h. The histopathological studies of the stages of extravasation were evaluated by means criteria .

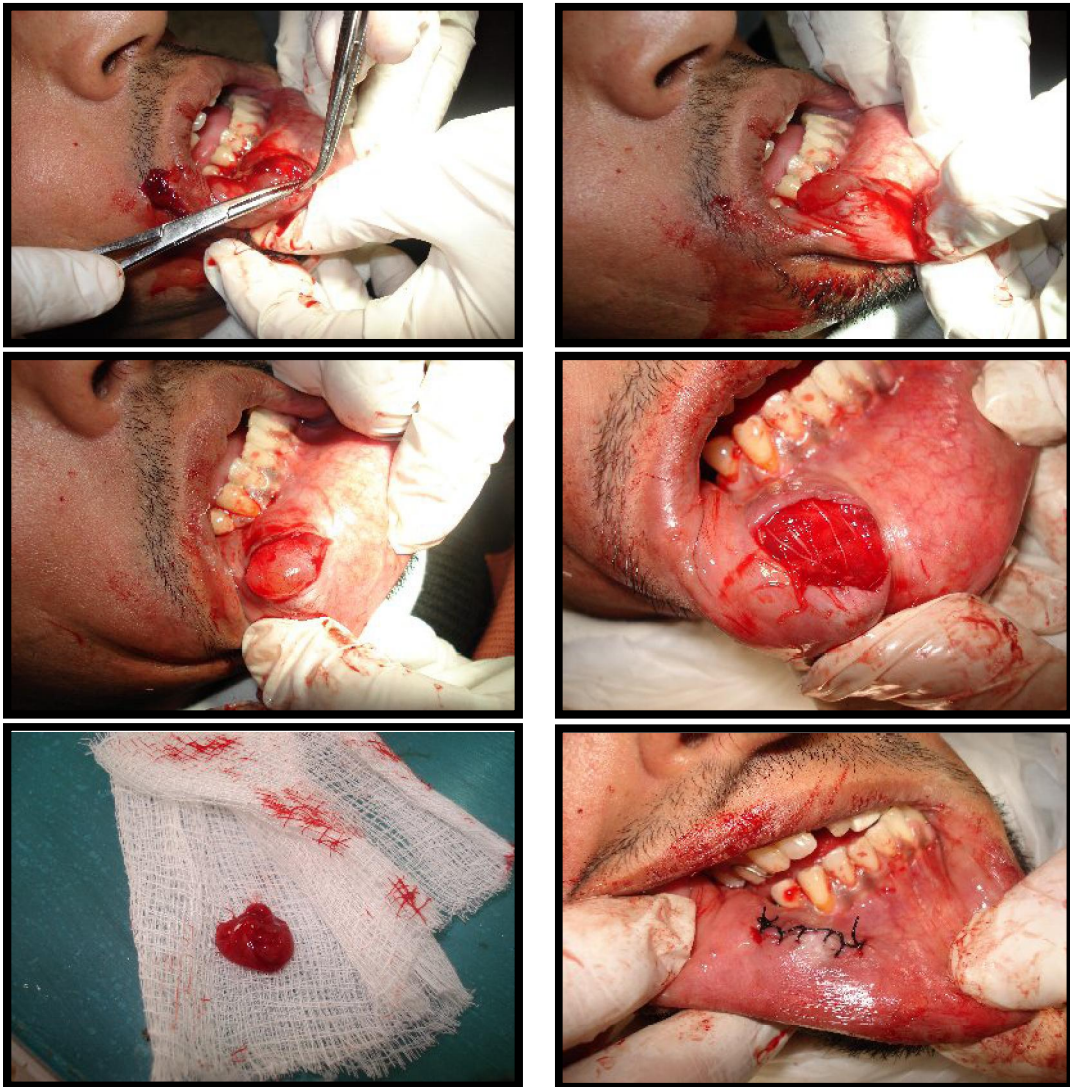**Fig.1: Pink non tender nodule on the inner mucosa of the lower lip.**



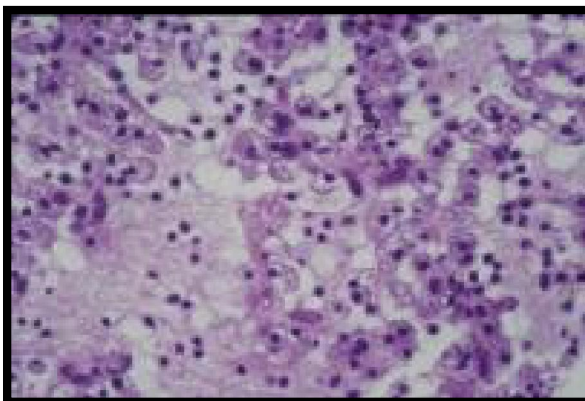
**Fig.2: Measurement of the size of oral mucocele**



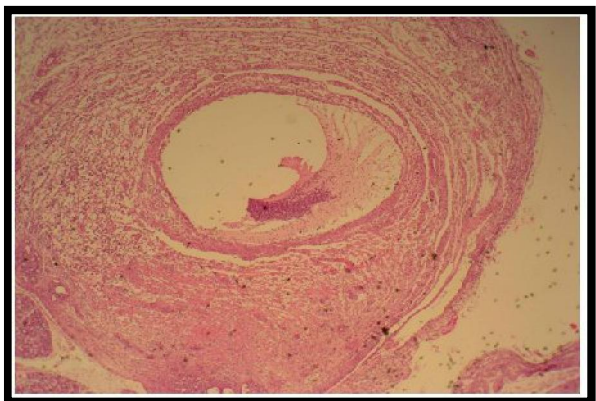
**Fig.3: Macroscopic images of extirpation of oral mucocele**



**Fig.4: microscopic picture**



**Fig.5: Histological image**





## Results

The age range was 5 to 65 years, with an average age of 25 years. Of the 18 subjects, 11 were males (61.1%) and 7 women (38.9%). All were of Caucasian origin. Only one mucocele occurred in the upper lip, the rest being in the lower

lip. One was bilateral. Most patients mentioned a gradual swelling of the lip (Table 1), of varying size. The interval from the time the patient first noticed the lesion to professional evaluation ranged from 3-24 weeks. The size varies.

**Table I: Patients clinical features**

	Age (y) & Sex	Evol. Wks	Color	Consist.	Diam. (mm)	Stage of Evolution	morphological Type	Recur.
1	5/f	4	Blue	soft	4x4	Resorped	Extravas.	No
2	65/F	10	Blue	Elastic	6x5	Resorped	Extravas.	No
3	6/M	14	Pink	Elastic	4x5	Final	Extravas.	No
4	24/M	8	Blue	soft	2x3	Final	Extravas.	Yes
5	23/M	22	Blue	soft	2x3	Final	Extravas.	No
6	54/M	6	Pink	Elastic	6x6	Initial	Extravas.	No
7	33/M	8	Blue	Elastic	4x5	Resorped	Extravas.	No
8	22/F	4	Pink	Elastic	9x9	Final	Extravas.	No
9	12/M	8	Blue	Elastic	6x8	Resorped	Extravas.	Yes
10	46/F	10	Blue	soft	2x2		Retention	No
11	10/M	12	Pink	Elastic	10x10		Retention	No
12	7/M	15	Blue	Elastic	2x3	Resorped	Extravas.	No
13	27/M	24	Pink	Elastic	15x15	Final	Extravas.	No
14	23/M	4	Blue	soft	5x5	Final	Extravas.	No
15	17/M	6	Pink	Elastic	5x5	Final	Extravas.	No
16	39/F	4	Pink	Elastic	2x2	Final	Extravas.	No
17	22/F	3	Blue	soft	2x3	Initial	Extravas.	No
18	25/F	12	Pink	Elastic	10x10	Final	Extravas.	No

Of the mucoceles examined, 88% were of the extravasation type and 11% retention.. Of the 16 classified as retention type, 12.5% were in the initial stage, 31.25% in the resorption stage and 56.25% in the final stage. All the mucoceles were extirpated surgically by the above described procedure and there were only two cases of recurrence in the one year follow-up period. No case of bleeding or secondary infection occurred and postoperative pain was minimal according to the patients' accounts.

## Discussion

This study confirmed that mucocele frequently occurs on the lower lip; however, the actual formation mechanism is still unclear, although it is

known to be favored by a traumatic etiology. The lesions can be located directly under the mucosa (superficial mucocele), in the upper sub mucosa (classic mucocele), or in the lower corium (deep mucocele). They usually occur singly and only very rarely bilaterally (only one case in our study). Mucoceles are painless asymptomatic swellings that have a relatively rapid onset and fluctuate in size. Clinical presentation depends on the depth of the lesion, while the color depends on the size and its nearness to the surface. Superficial MC; the mucus accumulates immediately below the mucosa, resulting in small translucent vesicles (0.1-0.4 cm in diameter) in the soft palate, the retromolar region, and the buccal mucosa.

In time, these blisters burst spontaneously or by trauma, leaving shallow ulcers or erosions. In the study we haven't found any cases of superficial mucocele. In the Classic MC, the size varies from a few millimeters to several centimeters in diameter, but 75% of the lesions are smaller than 1 cm in diameter. Eventually, the surface of the lesion turns irregular and whitish due to multiple cycles of rupture and healing caused by trauma or puncture. When the mucus accumulates in the deep soft tissues, the presentation is of an enlarging, painless mass assuming the pink coloration of the mucosa.

Diagnosis is made by clinical characteristics and confirmed by biopsy<sup>1-4</sup>. Patients with superficial MC require reassurance only<sup>8</sup>. Partial or total electrodesiccation and intralesional injections of triamcinolone acetonide have been reported as treatments of an MC; however, these are not routinely used. The most effective treatment is complete surgical extirpation of the lesion, including the immediately adjacent tissue. Aspiration of the mucocele contents often results in recurrence and is not appropriate therapy, except to exclude other entities prior to surgical excision<sup>1,7</sup>. In this study we haven't found secondary complications (infection, bleeding, pain), we observed only two recurrence occurred during the follow-up period. Surgical excision is the most commonly used method<sup>1,5,9</sup> although if extirpation is not complete

recurrence is frequent. Baurmash HD<sup>1</sup> showed that there are 3 possible approaches to the management of mucoceles of the lower lip which also apply. The small lesion can be completely excised, making sure to include the associated salivary gland tissue as well as any marginal glands before primary closure. Large mucoceles are best treated with an unroofing procedure (marsupialization). The third procedure involves the dissection of the mucocele along with the servicing mucous glands. This technique is performed on moderate sized lesions. As in the excision technique, all marginal glands should be removed before primary closure. Recently, the use of a micromarsupialization<sup>10</sup> technique for mucoceles in pediatric patients has been reported. This technique involves the placement of a 4.0 silk suture through the widest diameter of the lesion (dome of the lesion) without engaging the underlying tissue. A surgical knot is made, and the suture is left in place for 7 days. Patients need to be educated about suture replacement; they must return to have the suture replaced if it should be lost during the 7-day period. The idea behind this alternative treatment for mucoceles of minor salivary glands is that re-epithelization of the severed duct occurs or a new epithelial-lined duct forms, allowing egress of saliva from the minor salivary gland. The recurrence rate after a short follow-up period has been 14% in pediatric patients.

## References

1. Baurmash HD. Mucoceles and ranulas. *J Oral Maxillofac Surg*. 2003; 61: 369-78.
2. Bodner L, Tal H. Salivary gland cysts of the oral cavity: clinical observation and surgical management. *Compendium* 1991; 12: 150-6.
3. Yamasoba T, Tayama N, Syoji M, Fukuta M. Clinico statistical study of lower lip mucoceles. *Head Neck* 1990 ;12: 316-20.
4. Eversole LR. Oral sialocysts. *Arch Otolaryngol Head Neck Surg* 1987;113 : 51-6
5. Seifert G, Miehke A, Haubrich J, Chilla R. Diseases of the salivary glands. Stuttgart: Georg Thieme Verlag ,1986; 91-100.
6. Tran T, Parlette HL. Surgical Pearl: Removal of large labial mucocele. *J Am Acad Dermatol* 1999;40 :760-2
7. Crysedale WS, Mendelsohn JD, Conley S: Ranulas--mucoceles of the oral cavity: experience in 26 children. *Laryngoscope* 1988 ; 98: 296-8
8. Bermejo A, Aguirre J, López P, Saez R Superficial mucocele: Report of 4 cases *Oral Surg Oral Med Oral Pathol Oral Radiol End* 1999;88:469-72.
9. López Jornet P, Bermejo Fenoll A. ¿What is the most appropriate treatment for salivary mucoceles? Which is the best technique for this treatment *J Can Dent Assoc* 2004;7 :484-5.
10. Delbem AC, Cunha RF, Vieira AE, Ribeiro LL: Treatment of mucus retention phenomena in children by the micro- marsupialization technique: case reports. *Pediatr Dent* 2006; 22: 155-8.