

ONE STAGE COMBINED SURGICAL TREATMENT FOR DEVELOPMENTAL DISLOCATION OF THE HIP IN OLDER CHILDREN INCLUDING FEMORAL SHORTENING

Ali A Al-Iedan

MBChB, CABS, Lecturer in Orthopaedics, Department of Surgery, College of Medicine, University of Basrah, Basrah – Iraq.

Abstract

The treatment of developmental dislocation of the hip (DDH) in older children is a challenge because they have high displacement of the hip, contracted soft tissues, insufficiency of the acetabulum and increased anteversion of the femoral head. In such patients it is difficult to reduce the femoral head into the acetabulum, maintain the concentric reduction and obtain a satisfactory functional hip joint. The aim of this study is to assess the advantage and disadvantage of one stage combined surgery with femoral shortening in treatment of DDH in children above 2 years old.

This is a prospective study done in Al-Basrah General Hospital between (June 2008-June 2010), thirty patients were treated (35 hips), 28 females and 2 males. Five hips were right hip dislocation, 20 hips were left and 5 patients were bilateral. Femoral shortening done for all the hips and, in 28 hips pelvic osteotomy were performed at the time of open reduction. At the most recent follow-up (4 months-2 years) According to the radiographic criteria of Severin, 5 hips were excellent, 15 hips good and 10 hips have fair results, 5 end up hips had poor outcome.

Avascular necrosis developed in 5 of the 35 hips. All patients were followed with respect to range of motion and recovery from limb-length discrepancy. Different complications were recorded pre or postoperatively. Some complications like pelvic fracture (1 hip), subluxation and instability (3 hips), dislocation (2 hips) and stiffness (7 hips).

According to the rating system of McKay's clinical criteria, there were 7 hips excellent, 11 hips good, 12 hips fair results and 5 hips had a poor result.

It is concluded that children who are two years or older and have DDH, can safely be treated with an extensive one-stage operation consisting of open reduction combined with femoral shortening and pelvic osteotomy, without increasing the risk of avascular necrosis. The limb length discrepancy that is produced by the shortening does not appear to cause a clinical problem.

Introduction

The treatment of DDH is challenge in older children. Those patients have high displacement of the hip, contracted soft tissues, insufficiency of the acetabulum and increased anteversion of the femoral head^{1,2}. The problem lie in reducing the femoral head into the acetabulum maintaining the concentric reduction and obtaining a satisfactory functional hip joint³.

Ombredanne⁴ reported an operation that included open reduction with femoral

shortening in 1932. Combined operation of open reduction with femoral shortening, iliac osteotomy and reorientation of the femoral head & neck, have been used since 1963.

An osteotomy of the proximal part of the femur to shorten the femur has been recommended to avoid the complication of avascular necrosis, this operation allows the tight structures that cross the level of the osteotomy to function as if they were lengthened and does so more

effectively than a soft-tissue release.

Patients and Methods

This is prospective study of the clinical and radiological outcome of children who were (2.4/12-6.6/12 years) and had DDH that were treated at Al-Basrah General Hospital from (June 2008-June 2010). All of them were grade 3 or 4 according to the Tonnis⁵ radiological classification. Children who had a neuromuscular condition or who had received previous treatment for the dislocation were excluded.

There were 35 involved hips in 30 patients, 28 females and 2 males. Five hips were right and 20 hips were left and 5 cases were bilateral.

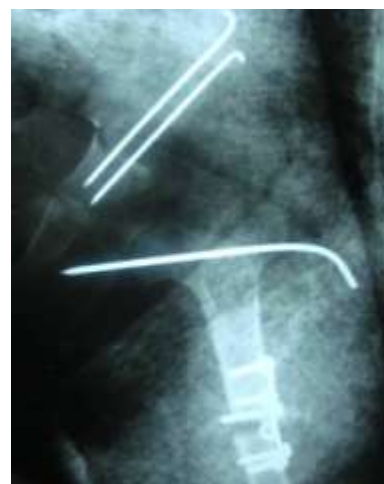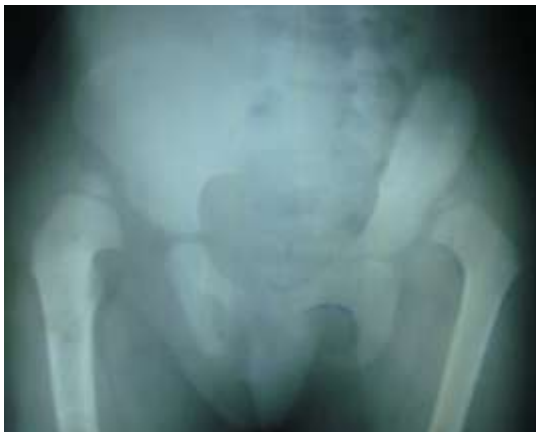Postoperatively, patients were evaluated for range of motion of the hip, limb length discrepancy and gait. Anteroposterior radiographs of the pelvis were done.

Operative Technique

All patients had open reduction through an anterior hip approach, after capsulotomy and excision of the hypertrophied ligamentum teres, gentle traction was applied to the extremity to assess the degree of contracture of the muscles that cross the hip joint. Due to the soft-tissue contracture, the femoral head still was not reducible without

applying excessive pressure even with adductor tenotomy.

Through a separate lateral approach, a transverse osteotomy was made in the subtrochanteric region. The two femoral fragments were allowed to overlap and reduction was obtained quite easily. A segment of femur that was 1-3 centimeters long, sufficient to relieve the muscular tension across the hip joint was then excised. If, at the time of the trial reduction of the hip, internal rotation of the femur seemed to contribute to stability of the joint, derotation was achieved by externally rotating the distal femoral fragment in relation to the proximal fragment before applying the plate. The hip was reduced concentrically and fixed by k-wire in most of the patients if coverage was inadequate a Salter or Dega pelvic osteotomy was performed. Postoperatively, the child wears a spica cast for six weeks. Fifteen patients needed blood transfusion during or after surgery, all patients were given third generation cephalosporin parenterally for the first 3 days. The spica and any pins that were used for fixation removed after 6 weeks under general anesthesia, then started physiotherapy but the weight bearing is not allowed till 12 weeks postoperatively.



(B)

Figure1: A anteroposterior radiography of 3 years child with bilateral DDH. B: after treatment with open reduction pelvic osteotomy and femoral shortening of the left hip.

Results

Of the 30 patients, the extent of limb shortening

The type of procedure	No. of the hips	Percent
Salter Pelvic Osteotomy	10	28. 57%
Dega Pelvic Osteotomy	18	51. 42%
Femoral head fixation by k-wire	25	71. 42%
Femoral Derotation	29	82. 85%
Adductors Tenotomy	35	100%
Femoral Shortening	35	100%

patients, of (limb

discrepancy) of the lower limb immediately postoperatively averaged 1.5 centimeters (0.5-3 centimeters). A pelvic osteotomy was necessary to stabilize the reduction in 28 of the thirty-five hips, 10 of these procedures (28.57%) were Salter innominate osteotomies and the remaining 18 (51.42%) were Dega. All hips were classified using the criteria of Severin⁶.

Table I: The surgical procedures that were performed with open reduction

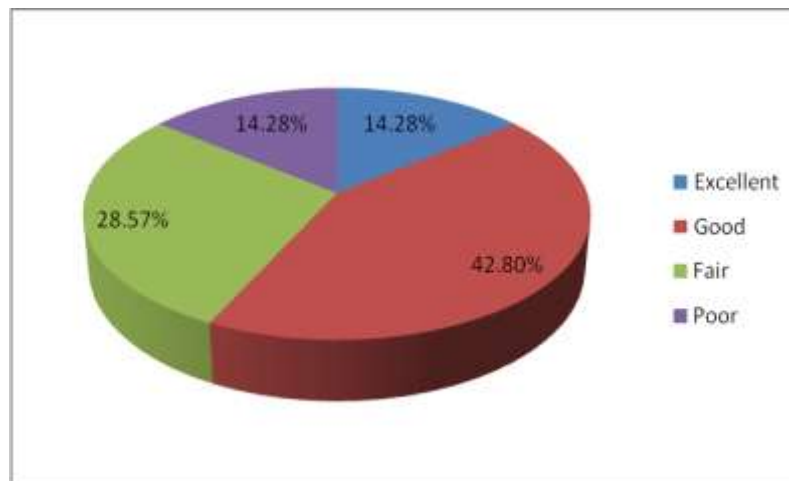


Figure 2: Our results according to Severin⁷ criteria for radiographic evaluation. Thirty five hips treated rated; class 1 excellent (5 hips) 14.28%, class 2 good (15 hips) 42.8%, class 3 fair (10 hips) 28.57%, class 4 poor (5 hips) 14.28%. Postoperatively all radiographs were evaluated for evidence of avascular necrosis, which was seen in 5 (14.28%) of 35 hips, when necrosis was present it fit the classification of Bucholz and Ogden⁷.

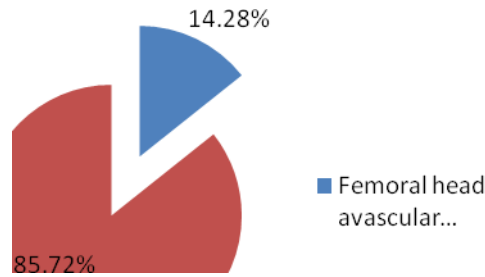


Figure 3: The incidence of the avascular necrosis of the femoral head postoperatively. The range of motion for our patients who returned for review was recorded and a score was assigned using the Mckay's rating criteria⁶, 35 hips were rated; excellent (7 hips, 20%), good (11 hips, 31.4%), fair (12 hips, 34.28%), poor (5 hips, 14.8%).

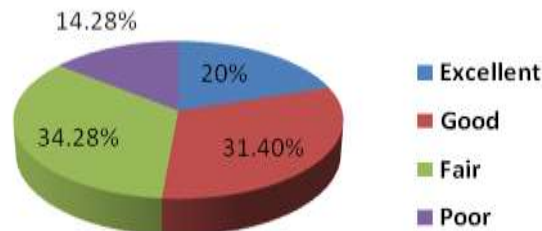


Figure 4: Our results according to Mckay's criteria⁷ for clinical evaluation.

Radiograph of bilateral femurs were used to document any residual limb length discrepancy that might have resulted from iatrogenic femoral shortening. A definite trend toward normalization of the length of the shortened limb was noted. Of the

25 patients who had a unilateral dislocation for whom radiogram could be made, at the latest follow-up, only 6 (17.14%) of these patients had a limb-length discrepancy of more than one centimeter (Figure 5).

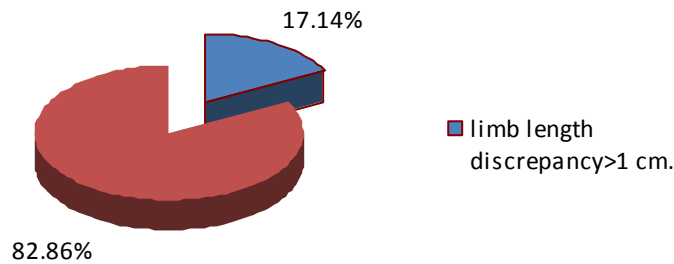


Figure 5: The incidence of limb length discrepancy >1cm post operatively.

Complications: The possibility of complications (table-II) was reviewed for all hips and there was; 1 patient (2. 85%) with pelvic fracture as a complication of pelvic osteotomy and treated by additional pin fixation.

Post operatively there were 2 dislocations (5.71%) which occurred few weeks after removal of the hip spica and their families refused further management.

In 3 patients (8.57%), subluxation and instability developed postoperatively, 1 of

these hips was diagnosed having subluxation 3 months postoperatively & was treated by cast for additional 2 months. The other 2 patients were treated by pelvic osteotomy which was not done in primary surgery.

Twenty hips (57.14%) had severe postoperative stiffness, 13 of them (37.14%) showed very good range of motion after physiotherapy and the remaining 7 hips (20%) continue to complaining from stiffness and pain.

Table II: The postoperative complications.

complications	No. of the hips	Percent
<i>infection</i>	0	0%
<i>Pelvic fracture</i>	1	2. 85%
<i>Redislocation</i>	2	5. 71%
<i>Subluxation and instability</i>	3	8. 57%
<i>Femoral head avascular necrosis</i>	5	14. 28
<i>Limb length discrepancy >1cm. post operatively</i>	6	17. 14%
<i>Residual hip stiffness and pain</i>	7	20%

Discussion

This study endeavor the use of primary femoral shortening at the time of open reduction of congenital dislocation of the hip in children who were two years or older.

Some authors have advocated skeletal traction for older and heavier children. Browne⁸ stated that soft-tissue release,

followed by a period of skeletal traction was abandoned in 1974 as being of little value. The complications in his patients included an increased incidence of infection from contaminated pin sites at the time of open reduction. The possibility of injury to the distal femoral physis and to the sciatic nerve are theoretical risks that are inherent in

treatment with traction. It has other advantages as well; it may be combined with open reduction, it avoids the prolonged hospitalization and risks of skeletal traction, and it allows more

adequate decompression of the joint than can be achieved by the conventional surgical release.

Femoral osteotomy, including shortening, varus osteotomy, or derotation osteotomy (or any combination) combined with open reduction, capsulorrhaphy and possibly pelvic osteotomy, has been considered by some to be a more extensive procedure than can safely be undertaken in one stage. Although we agree that it is a complicated procedure that should only be attempted by a surgeon with extensive experience, it can clearly be accomplished safely without a major increase in morbidity compared with open reduction alone. A satisfactory result (excellent or good) was achieved clinically in approximately 51.40% and radiographically in 57% of the hips in this series. This is a reflection of the fact that congenital dislocation of the hip in older children is a complex problem that has no easy solution.

Many studies suggested that the treatment of choice in older children was a one-stage combined surgical treatment with femoral shortening^{4,5,7-16}.

Whereas others performed open reduction and Salter innominate osteotomy in the same age group without femoral shortening^{6, 17-19}.

Avascular necrosis (AVN) is a serious complication in the treatment of DDH^{3,10,20,21}. The two major causes of AVN are excessive pressure on the cartilaginous femoral head, and occlusion of vessels of the femoral head¹⁰. Particularly in older children, the presence of high displacement of the hip, contracted soft tissues and increased anteversion of the femoral head may

complicate the reduction and encourage AVN of the femoral head^{9,11,22,14}.

Schoenecker and Strecker¹⁹ found 54% AVN rate in patients in whom open reduction was performed without femoral shortening. Femoral shortening allows easy reduction, reduces excessive pressure on the femoral head, and minimises necrosis of the cartilage and bone^{9,19,14}.

Tönnis²³ noted that the rate of ischaemic necrosis in open reductions was 8.2% for anterolateral approaches and only 5.5% when shortening osteotomy was combined with open reduction; a simultaneous Salter osteotomy or acetabuloplasty increased the rate to 10.3% and a concomitant varus osteotomy to 22.2%. In the present study, the AVN rate was, 14.28% in the patients who had one-stage combined operation including femoral shortening.

Gabuzda and Renshaw¹⁰ advocated that open reduction with femoral shortening was preferred in patients more than three years old.

Schoenecker and Strecker¹⁹ reported better results after one-stage treatment in children older than 3 years of age than after open reduction alone.

King and Coleman²⁴ noted that after the age of 4 years an open reduction combined with femoral shortening is often necessary to achieve optimum results. AVN rates in one-stage combined surgical treatment including femoral shortening have ranged from 0% to 11% in different studies :

Ashley *et al*⁹ 0%, Dimitriou and Cavadias⁴ 2.9%, Shih and Shih (37) 5%, Karakas *et al*⁵ 7.2%, Schoenecker and Strecker¹⁹ 7.6%, Williamson *et al*¹⁶ 11%. The age at the time of operation ranged from 2 to 7 years.

AVN rates of combined open reduction and pelvic osteotomy without femoral shortening ranged from 7.8% to 53.0% in different studies: Gür and Sarlak²⁴ 7.8%, Haidar *et al*²⁵ 8.0%, Salter *et al*²⁶ 15.0% and 30.0%, Gulman *et al*⁶ 34.6%,

Schoenecker and Strecker¹⁹ 53.0%; the age at the time of operation ranged from 1.5 to 8 years.

Conclusion

In a child two years or older, the treatment of congenital dislocation of the hip with one stage femoral shortening, open reduction, capsulorrhaphy, and, if necessary, pelvic osteotomy, is a difficult procedure, but its advantages include the avoidance of prolonged traction. We have shown that this procedure can be done safely, with reliable results without increasing the risk of avascular necrosis. The limb length discrepancy that is produced by the shortening does not appear to cause a clinical problem.

There is no doubt that these patients should be followed further, to find out whether degenerative arthritis or

additional AVN will develop. The definitive number of AVN in this small series remains uncertain, owing to the relatively short follow-up, considering that AVN may become apparent after as long as 10 years so it is so difficult to compare published results of various series of cases for they are evaluate differently and also have different periods of follow up.

Recommendation

Because of the less complications as compared with other studies, avoidance of prolonged time of hospitalization, the correction of associated femoral & acetabular deformities and without an increase in risk of avascular necrosis. So we recommend the use of one stage combined surgery for treatment of DDH in children above 2 years old.

References

1. Dimitriou JK, Cavadias AX. One-Stage Surgical Procedure For Congenital Dislocation Of The Hip In Older Children. *Clin Orthop* 1989 ; 246 : 30-38.
2. Karakas ES, Baktir A, Argun M *Et Al*. One-Stage Treatment Of Congenital Dislocation Of The Hip In Older Children. *J Pediatr Orthop* 1995 ; 15 : 330-336
3. Gulman B, Tuncay IC, Dabak N *Et Al*. Salter Innominate Osteotomy In The Treatment Of Congenital Dislocation Of The Hip : A Long Term Review. *J Pediatr Orthop* 1994 ; 14 : 662- 666.
4. Ombredanne L. *Précis Clinique Et Opératoire De Chirurgie Infantile*. Masson Et Cie Editeurs, Paris, 1932.
5. Developmental Dysplasia Of The Hip, www.Orthoreg.Org/Studyfiles, at 5. 20. 2009
6. G Tezeren, M Tukenmez, O Bulut, T Cekin, S Percin, One-Stage Combined Surgery With Or Without Preoperative Traction For Developmental Dislocation Of The Hip In Older Children, *Journal Of Orthopaedic Surgery* 2006;14 (3) :259-6
7. J. H. Beaty, Chapter 27, developmental dysplasia of the hip, S Canale and J. Beaty Campbell's Operative Orthopaedi, 11th Edition P1180-1188, Mosby
8. Browne RS. The Management Of Late Diagnosed Congenital Dislocation And Subluxation Of The Hip With Special Reference To Femoral Shortening. *J Bone Joint Surg* 1979 ; 61-B : 7-12.
9. Ashley RK, Larsen LJ, James PM. Reduction Of Dislocation Of The Hip In Older Children : A Preliminary Report. *J Bone Joint Surg* 1972 ; 54-A : 545-550.
10. Gabuzda BM, Renshaw TS. Current Concepts Review. Reduction Of Congenital Dislocation Of The Hip. *J Bone Joint Surg* 1992 ; 74-A : 624-631
11. Herold HZ, Daniel D. Reduction Of Neglected Congenital dislocation Of The Hip In Children Over The Age Of Six Years. *J Bone Joint Surg* 1979 ; 61-B : 1-6.
12. Klisic P, Jankovic L, Basara V. Long-Term Results Of Combined Operative Reduction Of The Hip In Older Children. *J Pediatr Orthop* 1988 ; 8 : 532-534.
13. Macewen GD. Treatment Of Congenital Dislocation Of The Hip In Older Children. *Clin Orthop* 1987 ; 225 : 86-92.
14. Shih CH, Shih HN. One-Stage Combined Operation Of Congenital Dislocation Of The Hip In Older Children. *J Pediatr Orthop* 1988 ; 8 : 535-539.
15. Wenger DR, Lee CS, Kolman B. Derotational Femoral Shortening For Developmental Dislocation Of The Hip. Special Indications And Results In The Child Younger Than 2 Years. *J Pediatr Orthop* 1995 ; 15 : 768-769
16. Willamson DM, Glover SD, Benson MKD. Congenital Dislocation Of The Hip Presenting After The Age Of Three Years. A Long-Term Review. *J Bone Joint Surg* 1989 ; 71-B : 745-751.
17. Haidar RK, Jones RS, Vergroesen DA *Et Al*. Simutaneous Open Reduction And Salter Innominate Osteotomy For Developmental Dysplasia Of The Hip. *J Bone Joint Surg* 1996 ; 78-B : 471-476. .
18. Kim NH, Park BM, Lee HM. Congenital Dislocation Of The Hip : A Long-Term Follow-Up In Korea. *Yonsei Med J* 1990 ; 31 : 134-143.
19. Schoenecker PL, Strecker WB. Congenital Dislocation Of The Hip In Children : Comparison Of The Effects Of Femoral Shortening And Of Skeletal Traction In Treatment. *J Bone Joint Surg* 1984 ; 66-A : 21-27.
20. James J. Mc Carthy, . Developmental Dysplasia Of The Hip. www.e-Medicine-Medscape.Com ; In 4. 3. 2009

21. Stuart L. Weinstein, developmental dysplasia of the hip, Chapter 15, Stuart L. Weinstein, Joseph A. Buckwalter Turek 'S Orthopaedic Principles And Their Application 6th Edition, Page 443-447.
22. Kalamchi A, macewen GD. Avascular necrosis following Treatment of congenital dislocation of the hip. *J Bone Joint Surg* 1980 ; 62-A : 876-888.
23. Tonnis D. Surgical treatment of congenital dislocation of the hip. *Clin Orthop* 1990 ; 258 : 33-40.
24. King HA, Coleman SS. Open reduction and femoral shortening in congenital dislocation of the hip. *Orthop Trans* 1980 ; 4 : 302-305. 27.
25. Gur E, Sarlak O. The Complications Of Salter Innominate Osteotomy In The Treatment Of Congenital Dislocation Of The Hip. *Acta Orthop Belg* 1990 ; 56 : 257-261.
26. Salter RB, Kostuik J, Dallas S. Avascular necrosis of the femoral head as a complication of treatment for congenital dislocation of the hip in young children. A clinical and experimental investigation. *Canadian J Surg* 1969 ; 12 : 44-50.