

POSTOPERATIVE ANALGESIA OF TRANSVERSUS ABDOMINIS PLANE BLOCK AFTER CESAREAN DELIVERY UNDER GENERAL ANESTHESIA

Hamed Abed-Alnabi Flaifel* & Hussein Abbas Muhalhil@

*MB,ChB, M.Sc, FICMS (anesthesia), Basrah Medical College. @MB,ChB. Basrah General Hospital.Basrah-Iraq. Correspondance to: flaifelhamed@yahoo.com,

Abstract

Cesarean delivery under general anesthesia requires effective postoperative analgesia for early ambulation and breast feeding. Transversus abdominis plane (TAP) block is done by injecting local anesthetic solution in the plane between internal oblique and transversus abdominis muscles on either sides of the abdominal wall to prolong postoperative analgesia.

One hundred pregnant women who underwent general anesthesia for cesarean delivery were randomized in to two equal groups;TAP block group versus control group. This block was performed bilaterally using 20 mls of 0.25% plain bupivacaine on each side. Each patient was assessed postoperatively by a blinded investigator at 2, 4, 6,12, 24 hours using numerical pain score (NPS) 0-10 at rest and movement. Narcotics consumption, drug side effects, and patient's satisfaction were recorded.

There were no significant differences between patients characteristics. Postoperative pain at rest as measured by NPS showed; medians (3-6) and means (3-5.5) in the control group; which were significantly ($p<0.05$) higher than those in TAP block group which did not exceed. During movement, NPS medians (4.5-8) and means (4.5-8.5) in the control group were significantly ($p<.05$) higher than those in TAP block group where never exceeded. Narcotic consumptions decreased to 50% in TAP block group. Pethidine requested by 30% of patients in the control group versus 14% of TAP group. Unilateral block observed in 1/50 (0.02%), no other complications reported from TAP block. Patients satisfactions for analgesia rated good by 82% in TAP block group versus 40% in control group.

In conclusion, transversus abdominis plane block provides good & prolonged postoperative analgesia after cesarean delivery performed under general anesthesia when it is combined to multimodal analgesia.

Introduction

The provision of effective postoperative analgesia after cesarean delivery is of key importance to facilitate early ambulation, infant care and prevention of postoperative morbidity¹. The analgesic regimen needs to meet the goals of providing safe, effective analgesia, with minimal side effects for the mother and her child. As part of a multimodal analgesic regimen, opioids are required initially to achieve effective analgesia. However, opioids are associated with dose-dependent side-effects², so that techniques which reduce opioid requirements may be of benefit in this population. The transversus

abdominis plane (TAP) block is regional anesthesia technique that provides analgesia to the parietal peritoneum as well as the skin and muscles of the anterior abdominal wall³.

Despite a relatively low risk of complications and a high success rate using modern techniques, TAP blocks remain underutilized⁴. Rafi first described this block in 2001; he portrayed it as a refined abdominal field block (RAFI), with targeted single shot anesthetic delivery in to the TAP, a site traversed by relevant nerve branches⁵. This was a significant advance from earlier strategies that required multiple injections⁶. By

utilizing surface anatomical landmarks; the TAP was reached by first identifying the lumbar triangle of Petit (figure D); an area enclosed medially by external oblique, posteriorly by the latissimus dorsi, and inferiorly by iliac crest. The floor of the triangle, from superficial to deep, is composed of skin, subcutaneous tissue, and the fascial borders of the external oblique, the internal oblique, and the transversus abdominis muscles, respectively. It is possible to block the sensory nerves of the anterior abdominal wall before they leave this plane and pierce the musculature to innervate the entire anterior abdominal wall⁷. In 2004 McDonnell et al presented preliminary work on TAP blocks in cadavers and in healthy volunteers at the scientific meeting of the American Society of anesthesiologists⁸, although this block was referred to as the RAFI technique, by the time the study was completed and published in 2007 McDonnell et al had already adopted the term TAP block⁹⁻¹⁰, and then demonstrated its postoperative analgesic utility in patients undergoing open retro pubic prostatectomy, lower abdomen operations¹¹⁻¹², and cesarean sections under spinal anesthesia¹³. There are different techniques for TAP block;

anatomical Landmark Based Approach as in Rafi's classic description⁵, Ultrasound-Guided Approach was first described in 2007 by Hebbard et al, and surgeon-Assisted Approach¹⁴⁻¹⁶. Chetwood et al¹⁷ described a laparoscopic-assisted technique wherein a classic TAP block based on anatomical landmarks was performed while the injection area is observed with an intra-abdominal laparoscopic camera. A peritoneal bulge at the area of injection was seen after local anesthetic was delivered within the TAP, and this visual served as the desired endpoint for this technique. Such direct visualization may help to avoid intraperitoneal injection, one of the major potential risks of the TAP block. More recently, a surgical TAP block utilizing a transperitoneal approach was performed intraoperatively, a blunt tipped block needle was advanced from inside the abdominal wall through the parietal peritoneum, then the transverses abdominis muscle, and as indicated by a single pop sensation¹⁷⁻¹⁹. Araco et al described a surgical TAP block in which blunt dissection through the external and internal oblique muscles leads to injection of local anesthetic into the TAP under direct visualization²⁰.

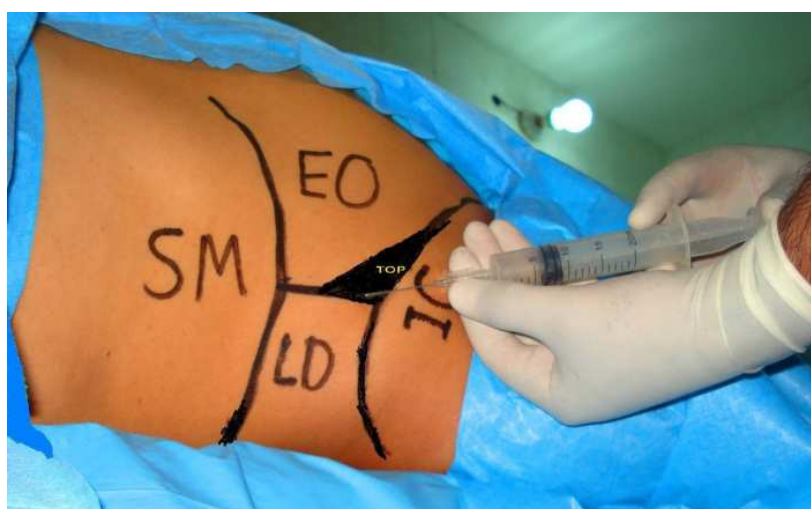

Figure 1: Lateral abdominal wall showing method of the block; TOP=triangle of Petit, SM= subcostal margin, IC=iliac crest, LD=Latissimus dorsi muscle, EO= External oblique muscle.

This study aimed to evaluate the postoperative analgesia of TAP block after cesarean delivery performed under general anesthesia.

Patients and methods

After obtaining an approval from the Ethical Committee, and written informed consents from the patients, one hundred full term pregnant women scheduled for elective cesarean delivery via a Pfannenstiel incision who underwent general anesthesia were included in the study. Their physical status were class I & II according to the American society of anesthesiology (ASA) classification for body fitness²¹.

The study was done at Basrah general hospital between 2nd January and 30th March 2011. Patients were excluded if there was a history of relevant drug allergy. Patients had been divided randomly into two equal groups: TAP block and control groups. TAP block was done with 20 mls of plain 0.25% bupivacaine (to a maximal dose of 1mg/kg/side), while patients of the control group did not receive block. The patients, anesthesiologists, and staff providing postoperative care were blinded to group assignment. All patients received standard general anesthesia by rapid sequence induction, consisting of pre oxygenation and intravenous injection of thiopental 250mg, ketamine 25mg, succinylcholine 100mg, endotracheal intubation, controlled ventilation, and maintenance with halothane 1% in 100% oxygen and relaxation by IV pancuronium 4mg. Syntocinon 10 international units was given IV after fetal delivery, and reversal of relaxation at end of surgery was done with IV neostigmine 2.5 mg mixed with atropine 1mg. The TAP block was performed at the end of operation, before extubation, by one investigator using the following technique¹² (Figure 1); a 22-gauge and 90-mm length spinal needle, Quinki type, was attached to a 20 mls syringe which was prepared under aseptic

technique. A loss-of-resistance technique was used to locate the TAP and this is possible because the fascial extensions of the abdominal wall muscles within the floor of the lumbar triangle of Petit create an easily appreciated increased resistance to needle advancement. With the patient in a supine position, the iliac crest was palpated from anterior to posterior until the latissimus dorsi muscle insertion was appreciated. The triangle of Petit was palpated between the anterior border of latissimus dorsi, the posterior border of the external oblique, and the iliac crest. The skin was prepared with 10% iodine solution, skin over the triangle of Petit was pierced with the needle held at right angles to the coronal plane. The needle was stabilized and advanced at right angles to the skin in a coronal plane until resistance was encountered. This first resistance indicated that the needle tip was traversing the fascial extension of the external oblique muscle. Further gentle advancement of the needle resulted in a loss of resistance, or "pop" sensation, as the needle entered the plane between the external and internal oblique fascial layers. Further gentle advancement resulted in the appreciation of a second increased resistance as the needle traversed the fascial extension of internal oblique. A second pop indicated entry into the transversus abdominis fascial plane. After careful aspiration to exclude vascular puncture, a test dose of 1 ml was injected. The reposition was done if substantial resistance to this injection was present which indicates that the needle was not between fascial planes. After a negative test dose, 20 mls of 0.25% bupivacaine (50mg) was injected through the needle whereas observing closely for signs of toxicity. The TAP block was then performed on the opposite side using the same technique. After recovery from anesthesia, patients were transferred to the obstetric ward where they received the same protocol of analgesia composed of diclofenac 75 mg intramuscular injection

every 12 hours at first 24 hours with adding of IM opioid (pethidine 50mg or tramadol 100mg) when patients requested more analgesia.

Assessment of the pain severity was done by numerical pain score (NPS) from 0-10 both at rest and movement by knee flexion on bed, and the presence of nausea and sedation were recorded. This assessment was done at 2nd, 4th, 6th, 12th and 24th hours after TAP block.

Statistical tests were performed using

SPSS™ v 18.0 for Microsoft™ Windows, and results were reported as absolute values, means, standard deviations, or medians with [25-75 inter-quartile range]. Z-test was used. A statistically significant difference is considered when p value is less than 0.05.

Results

The preoperative characteristics of patients for both groups were similar as seen in Table I.

Table I: Characteristics of patients

Characters		Groups	
		Control	TAP
Number (n)		50	50
Age (years)	mean ± SD	28.7±6.4	27.8±6.7
BMI (kg/m2)		27.39±2.62	27.75±3.38
ASA I/II		26/24	29/21
Parity median (range)		3(1-7)	3(1-8)
Patients with previous abdominal operations n (%)		31(62)	31(62)

Postoperative analgesia was measured by NPS (0-10) during rest and movement (Figures II & III). During rest postoperative pain in the control group showed NPS medians (3-6) and means (3-5.5) and these were significantly (p <0.05) higher than those in TAP block group in

which the NPS did not exceed 1 (Figures IIA & IIIA). Similarly, during movement the NPS medians (4.5-8) and means (4.5-7.5) in the control group which were significantly (p <0.05) higher than NPS in TAP group which never exceeded 2.5, as shown in Figures 2a & 2b.

Fig.2: A (At rest)

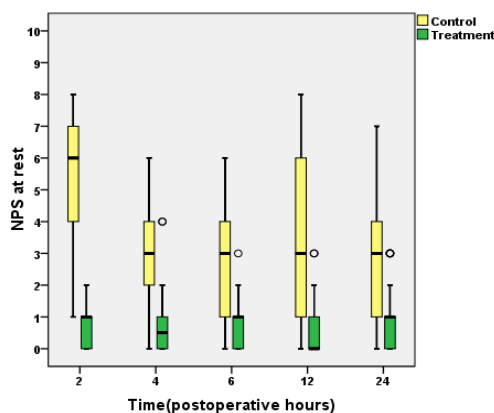


Figure 2, Box plots of postoperative numerical pain scores (NPS) at rest (A) and at movement with Knee flexion (B)

in each group over the first 24 postoperative hours. Control group is yellow and treatment (TAP block) group

is green in color. The thick line in each box represents the median value, the outer margins of the box represent the interquartile range, and the whiskers

represent the 90 and 10 percentile for each time point, circles indicate outliers while tars indicate extreme results.

Fig.2B (At movement)

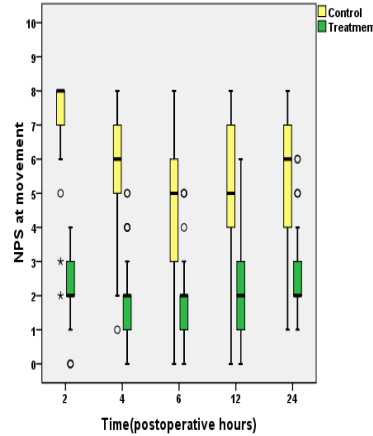
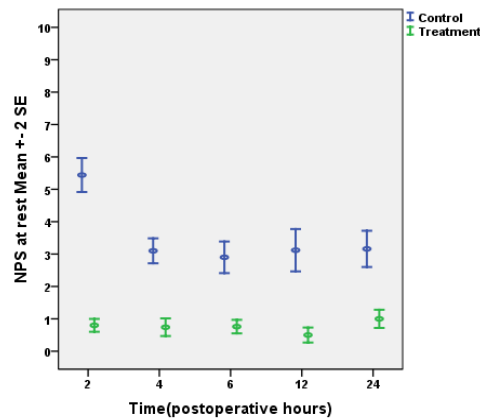
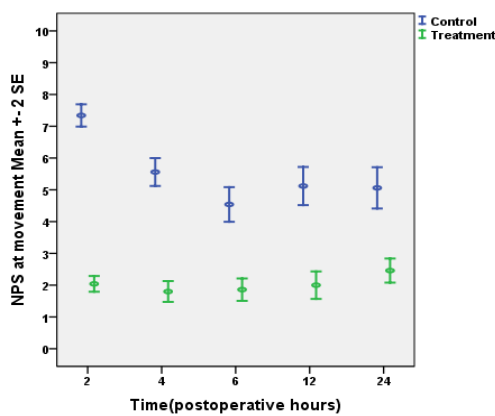


Figure 3: Postoperative numerical pain scores (NPS) at rest (A) and at movement with knee flexion (B) in each group over the first 24 postoperative hours. Control

group is blue while treatment group (TAP block) is green in color. Data are presented as means ± standard errors of means (SE).



The total narcotic consumption in both groups during the first 24 postoperative hours, is shown in (Figure IV); the TAP block group shows consumption of pethidine was 650mg and tramadol 900mg, which were about 50% less than those in the control group (pethidine 1250mg and tramadol 1800mg). At the 4th postoperative hour, about 30% of

patients in the control group as compared to 14% of patients in TAP block group requested IM injections of pethidine. However, tramadol IM injections were given at 6th postoperative hour to 36% of patients in control group as compared to 10% in TAP block group, as shown in table II.

Table II: Patients who were given narcotics in both groups.

Groups	Drugs IM	Postoperative hours				
		2hrs	4hrs	6hrs	12hrs	24hrs
Control (n=50)	Pethidine 50mg		15(30%)	3(6%)		7(14%)
	Tramadol 100mg			18(36%)		
TAP (n=50)	Pethidine 50mg		7(14%)			6(12%)
	Tramadol 100mg			5(10%)	4(8%)	

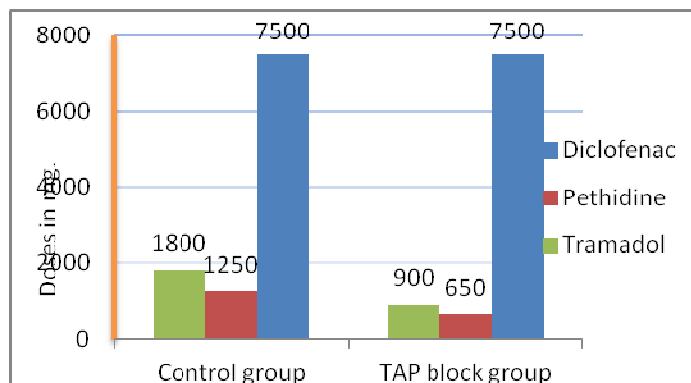


Figure 4: Total analgesic consumptions in both groups during the first 24 postoperative hours.

Postoperative nausea and vomiting or sedation episodes were not significantly different between both groups, P-value>0.05. However, patient's satisfaction with pain relief was rated as good by 82% of patients in the TAP block group and 40% in the control group with P-value<0.05.

Discussion

Transversus abdominis plane blocks have been described as an effective component of multimodal postoperative analgesia for a wide variety of abdominal procedures including large bowel resection, open/laparoscopic appendectomy, cesarean section, total abdominal hysterectomy, laparoscopic cholecystectomy, open prostatectomy, renal transplant surgery, abdominoplasty with/without flank lipo-

suction, and iliac crest bone graft^{16-20,22-49}. Most reports demonstrated the efficacy of TAP blocks by highlighting some combination of reduced postoperative opioid requirement, lower pain scores and/or reduction in opioid-related side effects.

The present study also demonstrated that supplementing a multimodal analgesic regimen with a TAP block resulted in reduced pain scores and reduced the overall postoperative analgesic requirements to about 50% in the first 24 postoperative hours compared with the conventional regimen used in the control group. The reasons for this long duration of analgesic effect after single-shot TAP blockade may be related to the fact that the TAP is relatively poorly vascularized, and therefore the clearance of bupivacaine

may be slowed⁵. The incidence of sedation was reduced in the TAP block group because of the smaller doses of the used opioids. There was a little non-significant difference in postoperative nausea and vomiting between both groups, this may be related to the effects of general anesthesia. When the duration of analgesia is an issue, there is good evidence to support using TAP catheters. This technique was first described in 2009 in a small case series⁵⁰. Two years later, the same group showed similar pain control between epidural and TAP catheter analgesia in randomized study²⁷. In both reports, an intermittent bolus protocol was used. Complications of the TAP block are rare; there are no published reports in the English language of local anesthetic toxicity following TAP blocks. Griffiths et al⁵¹ reported a mean peak plasma ropivacaine level of 2.54 ± 0.75 mcg/ml using a total dose of 3mg/kg to perform bilateral TAP blocks. While this level is above previously established minimum toxic plasma levels of 2.2 mcg/ml, it is similar to levels achieved in other commonly utilized peripheral nerve blocks (e.g., 2.58mcg/ml for axillary blocks)⁵¹. Kato et al. also suggested that toxic plasma levels may be achieved when using 40mL of 1% lidocaine⁵². Though direct intravascular injection of local anesthetics is very unlikely with TAP blocks, these studies do suggest that systemic toxicity is possible, and, as such, caution should be exercised throughout drug delivery⁵³.

Case reports of liver lacerations caused by right-sided TAP blocks can also be found in the literature. Farooq and Carey described a liver laceration after a landmark based TAP block⁵⁴. Upon laparotomy, the patient was subsequently found to have an enlarged liver that extended down to the iliac crest. As a

consequence, the authors recommended routine palpation of the liver edge prior to

landmark-based right-sided TAP blocks. Lancaster and Chadwick also reported a liver laceration after ultrasound guided TAP block, which was likely as a result of failure to adequately visualize the needle during the procedure⁵⁵. Furthermore, at least in theory, the spleen and kidneys are also at risk during TAP blocks. Jankovic et al⁵⁶ observed a TAP catheter in the peritoneal cavity upon surgical exposure of the abdomen for an open nephrectomy, however no reports of injury to these organs were found during a thorough literature search.

While the likelihood of needle placement may be minimized with the proper use of ultrasound guidance, the potential complication of femoral nerve blocks (partial or complete) may not be completely avoided. The transversalis fascia comprises the fascial plane deep to the rectus abdominis muscles. This fascial plane is continuous with the fascia iliaca. Local anesthetic injected into the TAP can theoretically track along the transversalis fascia to the fascia iliaca and, in doing so, may block the femoral nerve and place the patient at risk of a fall⁵³.

There are number of limitations to this study: first: the study limited assessment to the first 24 postoperative hours, because most of patients left the hospital at the next day of operation, second; the block was performed without ultrasound guide and third; the small size of the treatment group and these may not detect significant numbers of complications.

Conclusion: Transversus abdominis plane block, provides good & prolonged postoperative analgesia after cesarean delivery performed under general anesthesia when it is combined to multimodal analgesia.

References

1. Farragher RA, Laffey JG. Postoperative pain management following cesarean section. In: Shorten G, Carr D, Harmon D, et al., eds. *Postoperative pain management: an evidence-based guide to practice*. 1st ed. Philadelphia, PA: Saunders Elsevier, 2006:225–38
2. Dahl JB, Jeppesen IS, Jorgensen H, Wetterslev J, Moïniche S. Intraoperative and postoperative analgesic efficacy and adverse effects of intrathecal opioids in patients undergoing cesarean section with spinal anesthesia: a qualitative and quantitative systematic review of randomized controlled trials. *Anesthesiology* 1999;91:1919–27.
3. Charlton S, Cyna AM, Middleton P, and Griffiths JD. Perioperative transversus abdominis plane (TAP) blocks for analgesia after abdominal surgery. *Cochrane Database of Systematic Reviews*, vol. 8, Article ID CD007705, 2010.
4. Kearns RJ and Young SJ. Transversus abdominis plane blocks; a national survey of techniques used by UK obstetric anaesthetists. *International Journal of Obstetric Anesthesia*, vol. 20, no. 1, pp. 103–104, 2011.
5. Rafi, A. N. Abdominal field block: a new approach via the lumbar triangle. *Anaesthesia*, vol. 56, no. 10, pp. 1024–1026, 2001.
6. Atkinson RS, Rushman GB, and Lee JA. *A Synopsis of Anaesthesia*, Wright, Bristol, UK, 10th edition, 1987.
7. Netter FH. Back and spinal cord. In: Netter FH, ed. *Atlas of human anatomy*. Summit, New Jersey: The Ciba-Geigy Corporation, 1989:145–55
8. McDonnell JG, O'Donnell BD, Tuite D, Farrell T, and Power C. The Regional Abdominal Field Infiltration (R.A.F.I.) technique computerised tomographic and anatomical identification of a novel approach to the transversus abdominis neuro-vascular fascial plain, in *Proceedings of the American Society of Anesthesiologists Annual Meeting*, 2004, A-899. Abstract.
9. McDonnell JG, O'Donnell BD, Farrell T et al., "Transversus abdominis plane block: a cadaveric and radiological evaluation," *Regional Anesthesia and Pain Medicine*, 32, 5, 399–404, 2007.
10. McDonnell JG and Laffey JG. Transversus abdominis plane block. *Anesthesia and Analgesia*, 105, 3, 883, 2007.
11. O'Donnell BD, McDonnell JG, McShane AJ. The transversus abdominis plane (TAP) block in open retropubic prostatectomy. *Regional Anesthesia Pain Med* 2006;31:91.
12. McDonnell JG, O'Donnell B, Curley G, Heffernan A, Power C, Laffey JG. The analgesic efficacy of transversus abdominis plane block after abdominal surgery: a prospective randomized controlled trial. *Anesthesia Analgesia* 2007;104:193–7.
13. McDonnell JG, Curley G, Carney J, et al. The analgesic efficacy of transversus abdominis plane block after cesarean delivery: a randomized controlled trial. *Anesthesia Analgesia* 2008; 106: 186 – 91.
14. Hebbard P, Fujiwara Y, Shibata Y, and Royse C. Ultrasound-guided transversus abdominis plane (TAP) block. *Anaesthesia and Intensive Care*, vol. 35, no. 4, pp. 616–617, 2007.
15. Hebbard P. Subcostal transversus abdominis plane block under ultrasound guidance. *Anesthesia and Analgesia*, vol. 106, no. 2, pp. 674–675, 2008.
16. Børglum J, Maschmann C, Belhage B, and Jensen K. Ultrasound-guided bilateral dual transversus abdominis plane block: a new four-point approach. *Acta Anaesthesiologica Scandinavica*, vol. 55, no. 6, pp. 658–663, 2011.
17. Chetwood A, Agrawal S, Hrouda D, and Doyle P, "Laparoscopic assisted transversus abdominis plane block: a novel insertion technique during laparoscopic nephrectomy. *Anaesthesia*, vol. 66, no. 4, pp. 317–318, 2011.
18. Bharti N, Kumar P, Bala I, and Gupta V. The efficacy of a novel approach to transversus abdominis plane block for postoperative analgesia after colorectal surgery. *Anesthesia and Analgesia*, vol. 112, no. 6, pp. 1504–1508, 2011.
19. Owen DJ, Harrod I, Ford J, Luckas M, and Gudimetla V. The surgical transversus abdominis plane block—a novel approach for performing an established technique. *British Journal of Obstetrics and Gynaecology*, vol. 118, no. 1, pp. 24–27, 2011.
20. Araco A, Pooney AJ, Araco F, and Gravante G. Transversus abdominis plane block reduces the analgesic requirements after abdominoplasty with flank liposuction. *Annals of Plastic Surgery*, vol. 65, no. 4, pp. 385–388, 2010.
21. Editorial. New classification of physical status. *Anesthesiology* 1963;24,111.
22. O'Donnell BD, McDonnell JG, and McShane AJ. The Transversus Abdominis Plane (TAP) block in open retropubic prostatectomy. *Regional Anesthesia and Pain Medicine*, vol. 31, no. 1, article 91, 2006.
23. Sforza M, Andjelkov K, Zaccheddu R, Nagi H, and Colic M. Transversus abdominis plane block anesthesia in abdominoplasties," *Plastic and Reconstructive Surgery*, vol. 128, no. 2, pp. 529–535, 2011.
24. Kadam VR and Moran JL. Epidural infusions versus transversus abdominis plane (TAP) block infusions: retrospective study. *Journal of Anesthesia*, vol. 25, no. 5, pp. 786–787, 2011.
25. Hivelin M, Wyniecki A, Plaud B, Marty J, and Lantieri L. Ultrasound-guided bilateral transversus abdominis plane block for postoperative analgesia after breast reconstruction by DIEP flap," *Plastic and Reconstructive Surgery*, vol. 128, no. 1, pp. 44–55, 2011.
26. McMorro RCN, Ni Mhuircheartaigh RJ, Ahmed KA et al., "Comparison of transversus abdominis plane block vs spinal morphine for pain relief after Caesarean section. *British Journal of Anaesthesia*, vol. 106, no. 5, pp. 706–712, 2011.
27. Mei W, Jin C, Feng L et al. Bilateral ultrasound-guided transversus abdominis plane block combined with ilioinguinal-iliohypogastric nerve block for cesarean delivery anesthesia. *Anesthesia and Analgesia*, vol. 113, no. 1, pp. 134–137, 2011.
28. Niraj G, Kelkar A, Jeyapalan I et al. Comparison of analgesic efficacy of subcostal transversus abdominis plane blocks with epidural analgesia following upper abdominal surgery. *Anaesthesia*, vol. 66, no. 6, pp. 465–471, 2011.
29. Aveline C, Le Hetet H, Le Roux A et al. Comparison between ultrasound-guided transversus abdominis plane and conventional ilioinguinal/iliohypogastric nerve blocks for day case open inguinal hernia repair. *British Journal of Anaesthesia*, vol. 106, no. 3, pp. 380–386, 2011.

30. Gravante G, Castrì F, Araco F, and Araco A. A comparative study of the transversus abdominis plane (TAP) block efficacy on post-bariatric vs aesthetic abdominoplasty with flank Liposuction. *Obesity Surgery*, vol. 21, no. 3, pp. 278–282, 2010.
31. Allcock E, Spencer E, Frazer R, Applegate G, and Buckenmaier CIII. Continuous transversus abdominis plane (TAP) block catheters in a combat surgical environment. *Pain Medicine*, vol. 11, no. 9, pp. 1426–1429, 2010.
32. BaajJM, Alsatli RA, Majaj HA, BabayZA, and Thallaj AK. Efficacy of ultrasound-guided transversus abdominis plane (TAP) block for post-cesarean section delivery analgesia—a double-blind, placebo-controlled, randomized study. *Middle East Journal of Anesthesiology*, vol. 20, no. 6, pp. 821–826, 2010.
33. Heil JW, Feld BM 11, Loland VJ, Sandhu NS, and Mariano E R. Ultrasound-guided transversus abdominis plane catheters and ambulatory perineural infusions for outpatient inguinal hernia repair. *Regional Anesthesia and Pain Medicine*, vol. 35, no. 6, pp. 556–558, 2010.
34. Chiono J, Bernard N, Bringuier S et al. The ultrasound-guided transversus abdominis plane block for anterior iliac crest bone graft postoperative pain relief: a prospective descriptive study. *Regional Anesthesia and Pain Medicine*, vol. 35, no. 6, pp. 520–524, 2010.
35. Griffiths JD, Middle JV, Barron FA, Grant SJ, Popham PA, and Royse CF. Transversus abdominis plane block does not provide additional benefit to multimodal analgesia in gynecological cancer surgery. *Anesthesia and Analgesia*, vol. 111, no. 3, pp. 797–801, 2010.
36. Lee T H W, Barrington MJ, Tran TMN, Wong D, and Hebbard PD. Comparison of extent of sensory block following posterior and subcostal approaches to ultrasound-guided transversus abdominis plane block. *Anaesthesia and Intensive Care*, vol. 38, no. 3, pp. 452–460, 2010.
37. Kanazi GE, Aouad MT, Abdallah F W et al. The analgesic efficacy of subarachnoid morphine in comparison with ultrasound-guided transversus abdominis plane block after cesarean delivery: a randomized controlled trial. *Anesthesia and Analgesia*, vol. 111, no. 2, pp. 475–481, 2010.
38. Mukhtar K and Khattak I. Transversus abdominis plane block for renal transplant recipients. *British Journal of Anaesthesia*, vol. 104, no. 5, pp. 663–664, 2010.
39. Conaghan P, Maxwell-Armstrong C, Bedforth N et al. Efficacy of transversus abdominis plane blocks in laparoscopic colorectal resections. *Surgical Endoscopy and Other Interventional Techniques*, vol. 24, no. 10, pp. 2480–2484, 2010.
40. Araco A, Pooney J, Memmo L, and Gravante G. The transversus abdominis plane block for body contouring abdominoplasty with flank liposuction. *Plastic and Reconstructive Surgery*, vol. 125, no. 4, pp. 181e–182e, 2010.
41. Asensio-Samper JM, De Andrés-Ibáñez J, Fabregat Cid G, Villanueva Pérez V, and Alarcón LL. Ultrasound-guided transversus abdominis plane block for spinal infusion and neurostimulation implantation in two patients with chronic pain. *Pain Practice*, vol. 10, no. 2, pp. 158–162, 2010.
42. Costello JF, Moore AR, Wieczorek PM, Macarthur A J, Balki M, and Carvalho JCA. The transversus abdominis plane block, when used as part of a multimodal regimen inclusive of intrathecal morphine, does not improve analgesia after cesarean delivery. *Regional Anesthesia and Pain Medicine*, vol. 34, no. 6, pp. 586–589, 2009.
43. Jankovic ZB, Pollard SG, and Nachiappan MM. Continuous transversus abdominis plane block for renal transplant recipients. *Anesthesia and Analgesia*, vol. 109, no. 5, pp. 1710–1711, 2009.
44. Belavy D, Cowlshaw PJ, Howes M, and Phillips F. Ultrasound-guided transversus abdominis plane block for analgesia after Caesarean delivery. *British Journal of Anaesthesia*, vol. 103, no. 5, pp. 726–730, 2009.
45. Niraj G, Kelkar A, and Fox A J. Application of the transversus abdominis plane block in the intensive care unit. *Anaesthesia and Intensive Care*, vol. 37, no. 4, pp. 650–652, 2009.
46. Niraj G, Searle A, Mathews M et al. Analgesic efficacy of ultrasound-guided transversus abdominis plane block in patients undergoing open appendectomy, *British Journal of Anaesthesia*, vol. 103, no. 4, pp. 601–605, 2009.
47. El-Dawlatly AA, Turkistani A, Kettner S C et al. Ultrasound-guided transversus abdominis plane block: Anesthesiology Research and Practice 11 description of a new technique and comparison with conventional systemic analgesia during laparoscopic cholecystectomy *British Journal of Anaesthesia*, vol. 102, no. 6, pp. 763–767, 2009.
48. Carney J, McDonnell JG, Ochana A, Bhinder R, and Laffey J G. The transversus abdominis plane block provides effective postoperative analgesia in patients undergoing total abdominal hysterectomy. *Anesthesia and Analgesia*, vol. 107, no. 6, pp. 2056–2060, 2008.
49. McDonnell JG, Curley, G, Carney J et al. The analgesic efficacy of transversus abdominis plane block after cesarean delivery: a randomized controlled trial. *Anesthesia and Analgesia* vol. 106, no. 1, pp. 186–191, 2008.
50. Niraj G, Kelkar A, and Fox AJ. Oblique sub-costal transversus abdominis plane (TAP) catheters: an alternative to epidural analgesia after upper abdominal surgery. *Anaesthesia*, vol. 64, no. 10, pp. 1137–1140, 2009.
51. Griffiths JD, Barron FA, Grant S, Bjorksten AR, Hebbard P, and Royse CF. Plasma ropivacaine concentrations after ultrasound-guided transversus abdominis plane block. *British Journal of Anaesthesia*, vol. 105, no. 6, pp. 853–856, 2010.
52. Kato N, Fujiwara Y, Harato M et al. Serum concentration of lidocaine after transversus abdominis plane block. *Journal of Anesthesia*, vol. 23, no. 2, pp. 298–300, 2009.
53. Mark. Young J, Andrew. Gorlin W, Vicki. Modest E and Sadeq A. Quraishi. Clinical Implications of the Transversus Abdominis Plane Block in Adults. *Anesthesiology Research and Practice*. volume 2012, article ID 731645, 11 pages
54. Farooq M and Carey M. A case of liver trauma with a blunt regional anesthesia needle while performing transversus abdominis plane block,” *Regional Anesthesia and Pain Medicine*, vol. 33, no. 3, pp. 274–275, 2008.
55. Lancaster P and Chadwick M. Liver trauma secondary to ultrasound-guided transversus abdominis plane block. *British Journal of Anaesthesia*, vol. 104, no. 4, pp. 509–510, 2010.
56. Jankovic Z, Ahmad N, Ravishankar N, and Archer F. Transversus abdominis plane block: how safe is it?. *Anesthesia and Analgesia*, vol. 107, no. 5, pp. 1758–1759, 2008.