
**FOREQUARTER AMPUTATION FOR RECURRENT
EWING'S SARCOMA OF THE HUMERUS (CASE REPORT)****Jasim Hasan Amarah**

MB,ChB, FICMS, Orthopaedic Surgeon, Samawa-General Hospital, IRAQ

Abstract

A 27 year old male, known case of Ewing's Sarcoma of the right lower third humerus since July 2002, he was treated by combined therapy. After 3 years, he presented with pain, pathological fracture of the upper end of the right humerus and soft tissue mass around the right shoulder. Forequarter Amputation was done to him in October 2005. The presentation and management of this patient is discussed.

Introduction

Forequarter amputation consists of removal of the entire upper extremity and scapula girdle in the interval between the scapula and the thoracic wall. Usually it is indicated for malignant tumours which are preformed either through anterior (Berger) or posterior (little wood) approach¹. In recent years, emphasis on surgical resection in the treatment of Ewing's Sarcoma has increased; studies have demonstration reduced rates of local recurrences in surgically treated compared to radiation treated tumors. In addition to reducing the incidence of local recurrences, surgery appears to have an advantage over radiation therapy in term of long disease-free survival^{1,2-5}.

Case History

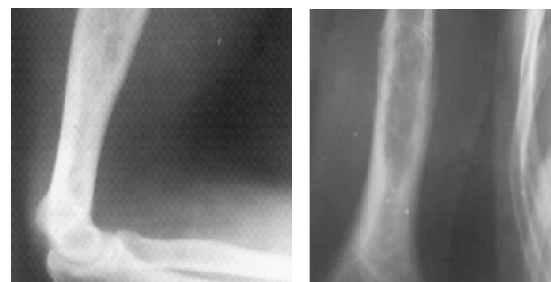
A 27 years old man from Samawa city was referred to our orthopaedic Outpatient Department on July 1st 2002 from rheumatologist. He has history of 3 months duration of pain and swelling of the right Lower end of arm. Pain worse at night and was associated with fever. Patient gives no history of trauma and he received treatment but with no

benefit. Initial examination showed diffuse swelling above the right elbow, no redness, the area was hot and tender. Movement in joints of the right upper limb was normal, peripheral pulses and sensation were intact.

Investigations; Blood tests were all normal a part from slightly raised ESR (28 mm/1hr).

Radiological examination:

Plain radiography of the right humerus and elbow showed peri-osteal reaction with loss of cortico-medullary junction at the middle and lower third of the humerus (fig.1). Chest x-ray was normal.

**Fig. 1**

Ultrasonography: Abdominal sonography was normal.

Histological examination: Biopsy was taken from affected area, the histopathological studies showed malignant round cell tumor with intervening connective tissue septa involving mainly the soft tissue and the muscle with focal area of bone involvement, a picture of Ewing's Sarcoma.

Post operatively patient was referred to oncology center in Baghdad (2002 to Aug. 2003), he received chemotherapy and radiotherapy. After that we lost till October, 9th 2005 when he consulted me again. At that time, patient had swelling of the right shoulder, pain and pathological fracture of the upper end humerus (fig.2), so he was admitted to the hospital.

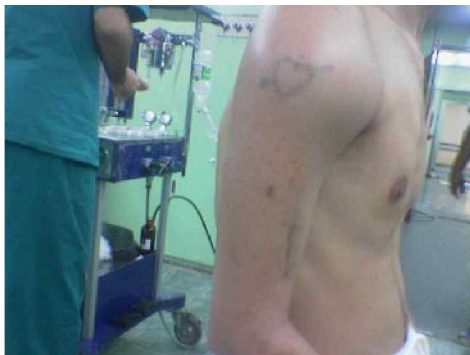

Fig. 2

Investigations:

Blood tests were normal apart from slightly raised ESR (30 mm/1hr) and marked high Lactate dehydrogenase (300 u/L).

Radiological examination:

Plain radiography of the right Shoulder (fig.3) showed soft tissue swelling with pathological fracture of upper end humerus and complete bone resorption. Chest x-ray was normal and abdominal sonography was also normal.

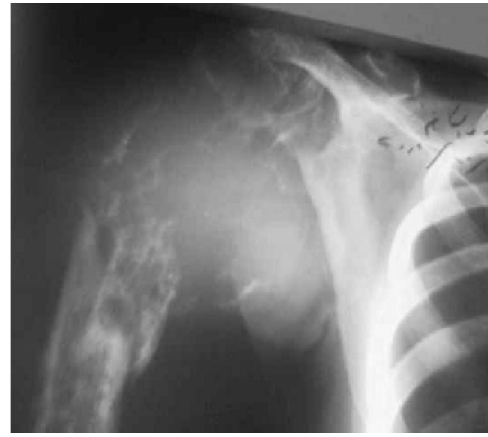

Fig. 3

On October, 19th 2005 and after wide discussion with the patient and his family we preformed forequarter amputation through anterior (Berger) approach. (Fig.4). Biopsy was taken and proved to be Ewing's sarcoma. The patient still alive till now, But he refused our advice about oncologist opinion post operatively.

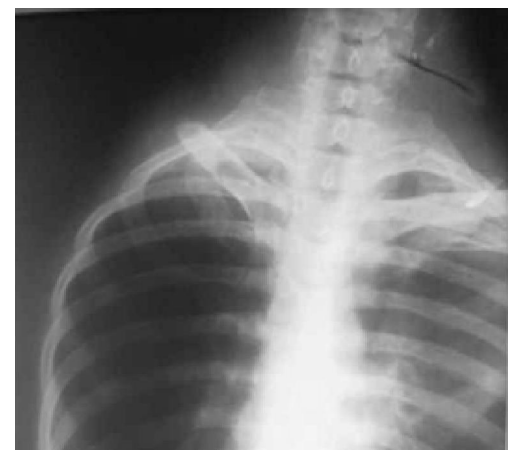
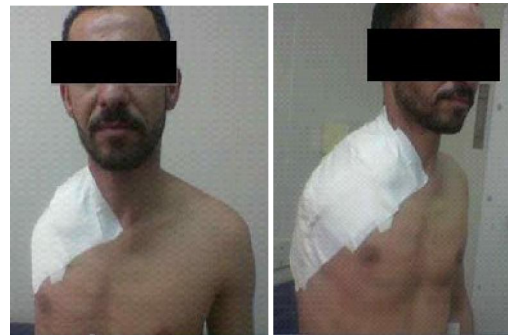
Fig. 4

Discussion

Ewing's sarcoma occurs most frequently in male in the second decade of life and presented usually with pain or mass or both. Fever, malaise, and other constitutional signs are not unusual. Radio-graphically; Ewing's sarcoma is lytic with permeative bone destruction, reactive subperiosteal reaction and large circumferential soft tissue mass. Biopsy is necessary to establish the diagnosis³

Treatment consists of chemotherapy, surgery and radiotherapy. However, as patients survive longer because of chemotherapeutic prevention of metastasis, local recurrences are being reported more frequently.

Some, advice amputation when the lesion is large in the presence of pathological fractures and in young children with distal lower extremity lesions.

Important prognostic factors are tumor stage, site (worst in the spine and pelvis), size of the tumor at presentation (Patient with tumors > 100 cm³ have a worse prognosis than patients with tumor with smaller size), and lactate dehydrogenase (LDH) level (elevated LDH is associated with worse outcomes)^{4,5}. Overall, the survival rate in patients with Ewing's sarcoma who receive combined treatment is 60%⁶.

In the case presented, forequarter amputation was selected for these reasons:

1. Presence of pathological fracture with complete bone resorption.
2. Large soft tissue mass around the shoulder.
3. Clinical suspicion of post radiation malignant transformation.
4. Lack of facilities to perform limb salvage or reconstruction.

References

1. Campbell's operative orthopaedics. Volume one 11th edition 2008.
2. Ozaki T, Hillmann A, Hoffmann C, et al: significance of surgical margin on the prognosis of patient(s) with Ewing's Sarcoma. A report the cooperative Ewing's Sarcoma study cancer 1996;78: 892.
3. Apley's system of orthopaedics and fractures.2001
4. Bacci G, Ferrari S, Bertoni F, et al. Prognostic factors in non-metastatic Ewing's Sarcoma of bone treated with adjuvant chemotherapy; analysis of 359 patients at the Istituto orthopaedic Rizzoli-J.Clino oncol. Jan.2000; 18(1) 4-11.
5. Orthopaedic Knowledge Update- 6.1999
6. Orthopaedic Knowledge Update- 7.2002