

## **TRANSVERSE PREPUTIAL ISLAND PEDICLE FLAP (TPIPF) IN TREATMENT OF FAILED HYOSPADIAS REPAIR: PERSONAL EXPERIENCE**

**Safaa A Mohssin**

FICMS(Urol.) Lecturer of Urology, Department of Surgery, College of Medicine, Basrah, Iraq.

### **Abstract**

This is a study to review the local experience with the use of TPIPF in the repair of failed hypospadias in order to improve the results in the future.

A total Number of 20 cases of failed Hypospadias was repaired during the period between 2001-2009 done in the public and private hospitals in Tikrit and Basrah. The repair was accomplished via Duckett method (transverse preputial island pedicle flap). The medical and operative records of each patient were registered and followed for 6 months. The success rate was 47% (9 patients). The complication rate was 55% in which urethro-cutaneous fistula was the commonest in 32% of the cases, meatal stenosis in 16%, urethral stricture in 10% and breakdown of the tube in 5%.

In conclusion, TPIPF remains a viable option in the management of failed hypospadias especially in the proximal type, the complications can be avoided by using the magnification loupes with perfect surgical technique and mandatory proximal urinary diversion.

### **Introduction**

The hypospadiology is rapidly expanding based on simple facts that none of the current methods of urethroplasty have been proved superior to the others in terms of achieving the goals of excellent functional and cosmetic results<sup>1</sup>. John W. Duckett, defines hypospadiology as "the in-depth study of the art and science of the surgical correction of hypospadias"<sup>2</sup>. The TPIPF for hypospadias was originally advocated by Asopa<sup>3</sup>. but Duckett developed and popularized it<sup>4,5</sup>. This is mainly because it can be applied to anterior, mid- and posterior penile hypospadias associated with or without chordee. The preputial skin, with its accompanying superficial fascia and vessels, is ideal for the construction of flaps for hypospadias repair<sup>6</sup>. It is relatively thin and pliable; it has good blood supply that can be mobilized as pedicle. It also tolerates prolonged

contact with urine better than any tissue other than bladder mucosa<sup>7</sup>. Correction of a repeatedly failed hypospadias repair is a surgical challenge because the repair is done using surgically damaged tissues which may be inadequate for the repair. The correction of a hypospadias repair may be very similar to a primary repair, but it can be also be difficult because of the badly vascularized tissues at the repair site<sup>8</sup>.

### **Patients and Methods**

This is a retrospective study of 20 cases of failed repaired hypospadias with intact prepuce (mid- and proximal penile) managed with TPIPF between 2001 to 2009 and operated upon by the same urologist. The case notes were recorded as follows: age of patient, type of hypospadias, presence or absence of chordee, use of stent, making of urinary diversion and duration, history of

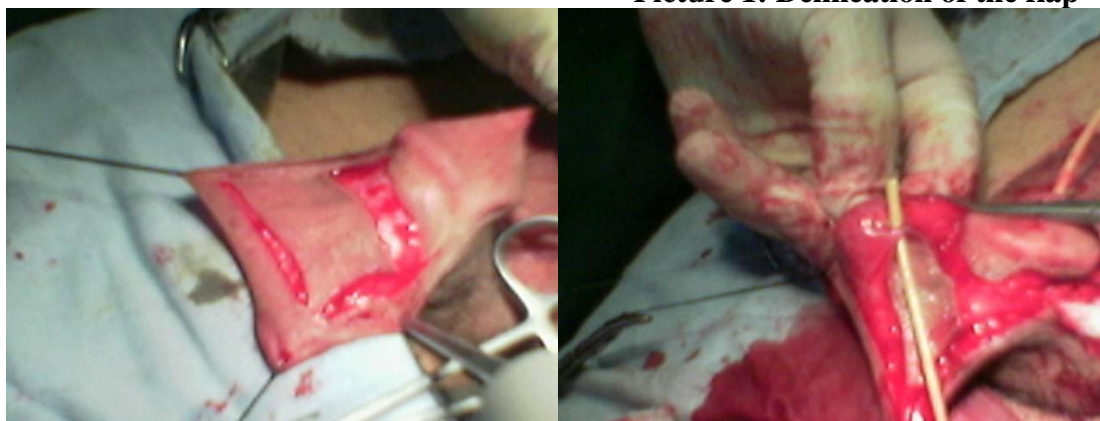previous repair, complications after repair (bleeding, meatal stenosis, urethro-cutaneous fistula, infection, urethral diverticulum, urethral stricture and breakdown of the repair). All cases were followed for 6 months

### Surgical technique

The applied technique is as described by duckett<sup>4,5</sup>. Optical magnification was not used because operative microscope and loupe were not available in the centers where the study has been done. 3\0 silk traction suture were applied to the dorsum of the glans penis and artificial erection was induced by injection of 10-15 ml of normal saline by a butterfly needle in each corpus cavernosum to diagnose and assess severity of chordee. A circumferential incision is made proximal to the corona and hypospadias orifice. The urethra and shaft skin were dissected free of corpora cavernosa to release the chordee tethering. An artificial erection is induced again to re-assess the chordee. The native urethra was brought to comfortable position without tension on the shaft and fixed by 5\0 vicryl suture to the tunica albuginea. A transverse island from inner layer of prepuce was outlined and dissected with

the distance equal to or slightly longer than that between hypospadias orifice and the tip of glans as measured with a strip of suture, the width was measured subjectively based on the age of the patient. The flap was dissected with its axial vascular pedicle which was mobilized proximally to an extent that allowed ventral transposition of the flap with no tension. The islands flap was tabularized such that it was slightly loose around a suitable sized stent using subcuticular and 2nd interrupted layer by 5\0 PDS suture. The neo-urethra was transported ventrally and anastomosed to the native urethra using 5\0 interrupted vicryl suture. A glans channel was constructed by excising central core of glandular tissue to the level that make the glandular edges cover the neo-urethra which was brought through the glans and the glandular edges sutured by 4\0 dexon (mattress). The dorsal layer of prepuce was transported ventrally and the repair covered with skin as cosmetically as possible. Perineal urethrostomy catheter of 10-14Fr. was placed as proximal urinary diversion and kept in situ for 14-21 days and the stent in the flap left in situ (neo-urethra) for 10-14 days.

**Picture 1: Delineation of the flap**



**Picture 2: Tubularization**

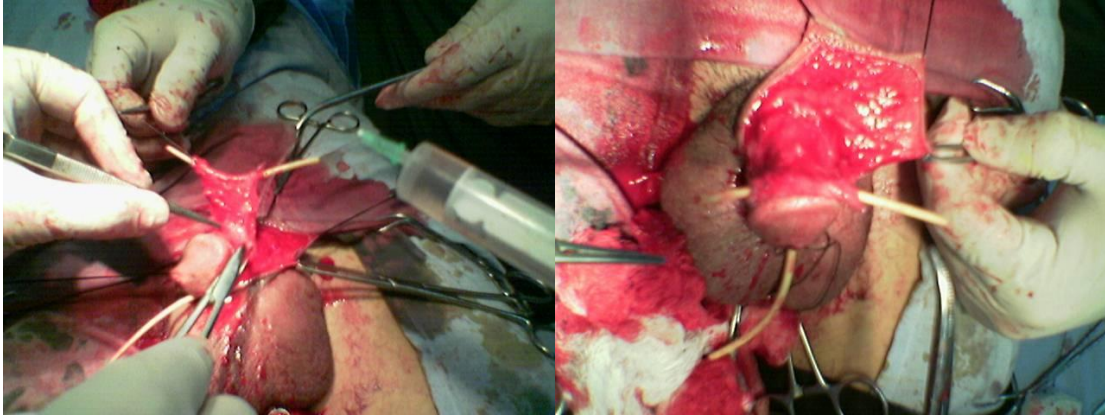
The patients were followed up in and the mothers were asked to describe urinary stream which was also visually

assessed (the centre lack the uroflowmetry). If the flow of urine was poor, urethral calibration was instituted

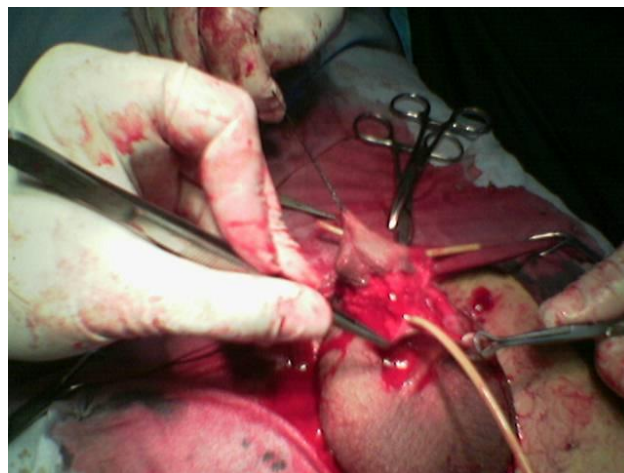usually as day case procedure. In patients with postoperative strictures, urethroscope and dilatation were also done. All patients were followed up for

6 months with some difficulties with follow-up of few patients because once the problem was over; some patients hardly keep coming to an appointment.

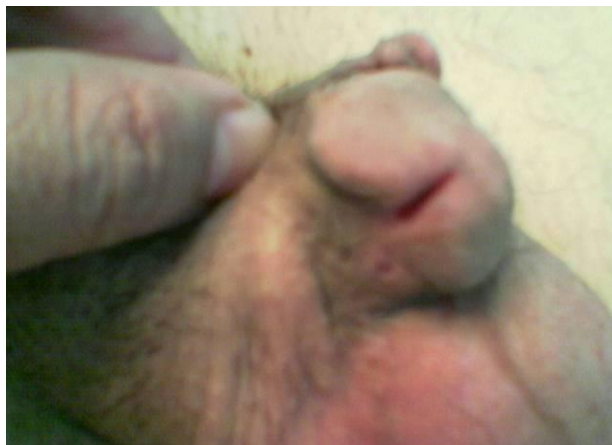**Pictures 3&4: Completion the tubularization**



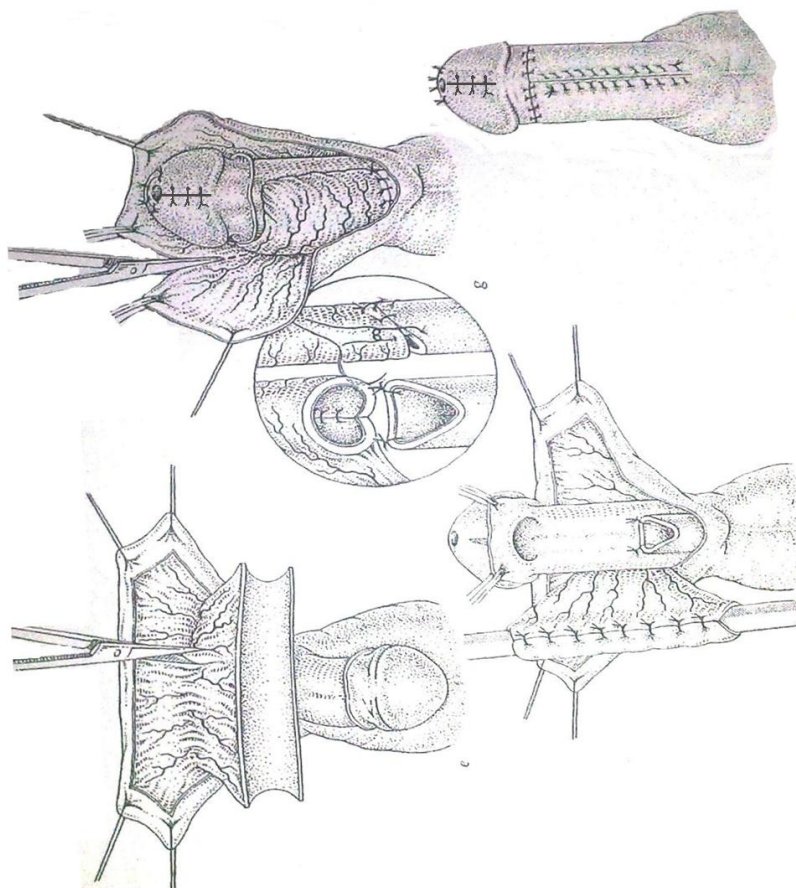
**Picture 5: Rotation of neo-urethra and anastomosing it**



**Picture 6: After operation**



**Figure 1: Steps of TPIPF, From; *Operative Paediatric Urology* by J.David, churchil livingstone**



### Results

During the period 2001-2009, a total of 20 cases of previously failed hypospadias repaired by TPIPF were included in the study. Sixteen cases (80%) had mid-penile hypospadias and 4 cases (20%) had proximal hypospadias (Table I).

The distribution of cases among different age groups was 14 cases (70%) aged 5-10 years, 4 cases (20%) aged 10-15 years and 2 cases (10%) aged 15-20 years as shown in table II.

The complication rate was (55%), (Table-III), with frequency as follows: Urethro-cutaneous fistulae occurred in 7 cases (32%), 3 of them healed spontaneously, 4 cases need ed

fistulorrhaphy after 6 months. The commonest age group affected was 5-10

years with incidence of 60% of all cases of fistulae (Table IV), with urethro-cutaneous fistulae incidence of 71 % (5 cases) in mid-hypospadias as shown in table V. The 2nd complication was meatal stenosis in 3 cases (15%). Urethral stricture occurred in 2 cases (10%).

### Discussion

Correction of previously failed hypospadias considered one of the difficulties because of the badly vascularized scarred tissues at the repair site that impair healing. But in the

presence of intact prepuce, this will give us a hope in the correction of the defect, but unfortunately if the patient had no preserved prepuce, one must think about non-genital grafts that carries a lot of complications<sup>9</sup>. The choice of TPIPF for correction of the defect is in spite of some surgical difficulties of the relatively lengthy operative time, because this is the only lengthy healthy tissue preserved that can be used to repair even the proximal hypospadias as also mentioned by other articles<sup>4,10</sup>.

The sample size was collected over 9 years. It is small and this can be explained by the selection of cases with previously failed repair and at the same time they have intact prepuce.

There were a lot of patient with failed repair and had no prepuce (preputial island flap were used or circumcision was done either by family or surgeon at the time of 1st repair), this made limitation in the study sample to 20 cases, larger sample being looked for in the future.

From this study, it's clear that the tubularized preputial islands flap is considered as a suitable option for repair of scarred ventral penile skin provided that the prepuce is not removed or used in a previous repair<sup>4,5</sup>. The inner preputial skin provides one of the most suitable epithelial structures for creating a neo-urethra up to 6-7cm long; its vascular pedicle can be dissected proximally to be adapted to different varieties of hypospadias.

The complication rate was 55%, the commonest one that associated with hypospadias repair was fistula formation and the incidence of this complication varies in various reports on this procedure<sup>10-13</sup>. Duckett himself reported an incidence of 10%<sup>4,5</sup>. The wide variability in fistula rate among these studies (17-34%) can be explained by technical differences and the severity of hypospadias. In this study, the incidence is 35% which is relatively high in

comparison with the other studies and this can be explained by the absence of some instruments that are used in modern surgical repair like magnification loupes and fine surgical sets that ensure inversion of epithelial surface toward lumen during suturing in addition to that<sup>2</sup>, patients with fistulae found to have meatal stenosis, this could predispose to fistula formation<sup>5</sup> and increase its incidence<sup>14,16</sup>. There is no significant statistical relationship between fistula formation and age.

Severe bleeding was faced from the glans dissection in one patient (14 years of age and controlled by multiple ligation of the bleeders by using 5\0 PDS with little compression by dressing). Unfortunately, this patient ended with breakdown of the tube after 6 days. This can be explained by the effect of compression on blood supply of the flap and resulted in impedance of healing followed by breakdown of the tube<sup>15</sup>.

Meatal stenosis is the 2nd most common complication in this study that occurred in 3 patients (15%) in comparison with other studies, that reported rates of (9-30%)<sup>8,10,16</sup>, and by checking the operative reports of these operations, explanation is that there was technical surgical problem in making enough glans dissection to make tension free channel for neo-urethra resulted in glans meatal stenosis later on<sup>15,16</sup>; Those patients were treated by meatotomy after failure of meatal dilatation.

Regarding urethral stricture occurred in 2 patients (10%) at the anastomosis of neo-urethra with the native urethra. This is an acceptable incidence if compared with other articles which reported (10-20%)<sup>5,10,16</sup>. Both occurred in proximal hypospadias which appeared to be at particular risk for stricture. This is also reported by others<sup>15</sup>, this may be attributed to the length of neo-urethra which is longer than the neo-urethra in mid-penile hypospadias. One of them

treated by dilatation and the other by optical urethrotomy<sup>10,16</sup>. Regarding the No. of patients with proximal hypospadias, it was smaller than the mid-penile hypospadias, this is

because of the TPIPF considered the procedure of 1st choice in the repair of proximal hypospadias so most of the cases have no intact prepuce in the 2nd repair apart of these 4 cases where treated by scrotal on-lay flap.

Regarding urinary diversion, it was preferred to do perineal urethrostomy because it is easier, safer and give accurate functional diversion (more than supra-pubic) because the bladder neck and the prostatic urethra are located at the most dependant part in the bladder which may result in urinary leak even with suprapubic diversion in comparison with occlusion of prostatic urethra by the urethrostomy tube. The duration of diversion ranged between 2 to 3 weeks to give enough time for healing process with lower incidence of fistula formation. This was also reported by others as they keep diversion for 2-3 weeks also<sup>5,10</sup>.

In conclusion, the TPIPF is the salvage operation for failed hypospadias with extensive penile scarring supposing they have intact prepuce, so circumcision is not recommended in any repair until the complete success of any repair. The successful rate can be improved by using the modern magnification instruments to ensure inversion of epithelial surface and to preserve the arterial blood supply of the flap. Tight dressing is not recommended and proximal urinary diversion is mandatory.

**Table I: Classification of patients according to the site of hypospadias**

	Mid-hypospadias	Proximal hypospadias	Total
Number of patients	16 (80%)	4 (20%)	20

**Table II: Distribution of cases among different age groups.**

Age groups	5-10 years	10-15 years	15-20 years
No. of patients	14(70%)	4(20%)	2(10%)

**Table III: Incidence of complications**

Complications	No. of Patients
Bleeding	1(5%)
Urethro-cutaneous fistula	7(35%)
Meatal stenosis	3(15%)
Urethral stricture	2(10%)
Breakdown of repair	1(5%)
Total	11

Note: More than one complication occurred in one patient, that result in difference between number of each complication and the total number

**Table IV: Distribution of Urethro-cutaneous fistulae among different age groups**

Number of patients with UCF	5-10 years	10-15 years	15-20 years
	4(57%)	2(29%)	1(14%)

**Table V: Distribution of urethro-cutaneous fistula between the 2 types of hypospadias**

Number of patients with UCF	Mid-penile hypospadias	Proximal-penile hypospadias	Total
	5(71%)	2(29%)	7

**References**

1. Gangopadhyay AN, sharmas, Mongha R. Onlay Preputial flap for mid and distal hypospadias. J India assoc Pediatric Surgery 2005; 10:244-7.
2. Elder JS,Duckett JW.Urethral reconstruction following an unsuccessful one stage hypospadias repair.World J Urology1987;5:19-6
3. Asopa HS,Eihence EP,Atri SP,Bansal NK.One stage correction of penile hypospadias using a foreskin tube: a preliminary report,Int. Surgery 1971; 55:435-40.
4. Duckett JW Jr.Transverse preputial island flap technique for repair of hypospadias .Urol clinic N Amer 1980;7:423-30
5. Duckett JW.The island flap technique for hypospadias repair .Urol clinic north America.1981;8:503-8.
6. Elbakry A. Complication of the preputial island flap-tube urethroplasty,BJU Int. 1999;84:89-94.
7. Hinman F Jr.The blood supply to preputial island flap.J Urol 1991;145:1232-5
8. Bracka A .Along-term view of hypospadias Br.J.Plast.Surgery.1999;42:251-5.
9. Snyder CL,Evangelidis A , Hansen G et al.Management of complications after hypospadias repair. Urol 2005;65:782-5.
10. Sowande AO,Olajidi AO, Salako AA , Olajidi FO.Experience with tyransverse preputial island flap for repair of hypospadias .African journal of paediatric Surgery 2009;6:40-43
11. Jayanthi VR,Mcloire GA,Khoury AE,Churchil BM,Functional characteristics of the reconstructed neo-urethra after island flap urethroplasty.J Urol 1995;153:1657-59
12. Patel RP,Shukla AR,Austin JC, et al.modified tubularized transverse preputial island flap repair for severe proximal hypospadias BJU Int.2005;95:901-904
13. Dewan PA,Dinnen MD,Winkle D,Duffy PG, Ransley PG Duckett pedicle tube urethroplasty – Eur Urol 1991;20:39-42.
14. Parsons K,Abererombie GF.Transverse preputial flap neo-urethroplasty.BrJ Urol 1982;54:745-7.
15. Retik AB , Borer JG:Hypospadias In walsh PC:Campell's urology,9th edition ,Philadelphia, WB Saunders,2007;vol.6,3739-3741
16. Sami A,Anuar IM.Peno-scrotal hypospadias. Braz J Urol. 2000;26(3):304-314.