

TENSION PNEUMOTHORAX AS A RARE PRESENTATION OF PULMONARY HYDATID CYST: A REPORT OF TWO CASES FROM IRAQ

Abdulsalam Y Taha* & Jaffar Shehatha[@]

*MB,ChB, FICMS, Professor and Head of Dept. of Thoracic and Cardiovascular Surgery, College of Medicine, University of Sulaimania, Iraq. [@] MB,ChB, FICMS, FRCS, FRACS, Senior Lecturer, University of Western Australia, Perth, Australia.

Correspondence to: DR. ABDUSALAM Y TAHA, E MAIL: Salamyt_1963@Hotmail.Com

Introduction

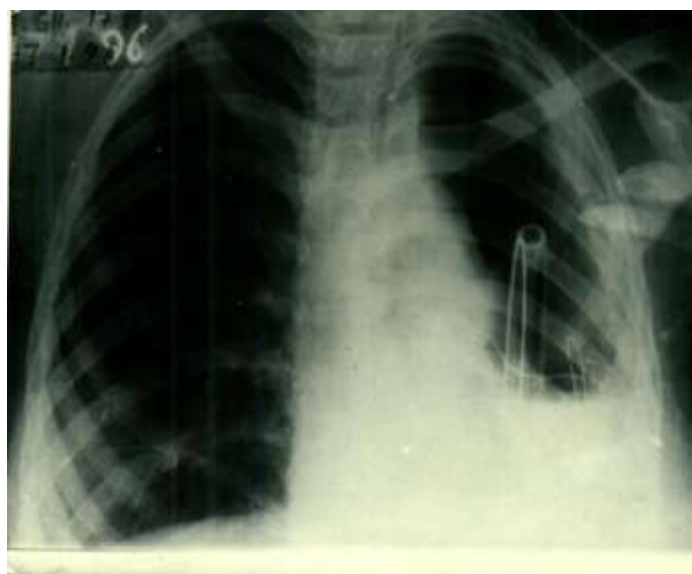
Tension pneumothorax secondary to rupture of pulmonary hydatid cyst (PHC) is rare¹⁻⁵. It was first reported by Waddle N from Australia in 1950⁶. In Iraq, it was reported for the first time by Bakir F and Al-Omeri M in 1969². Herein, we present two more cases from Iraq. The aim is to emphasize that intra-pleural rupture of PHC should be considered in any patient presenting with pneumothorax in an endemic area.

Case Histories

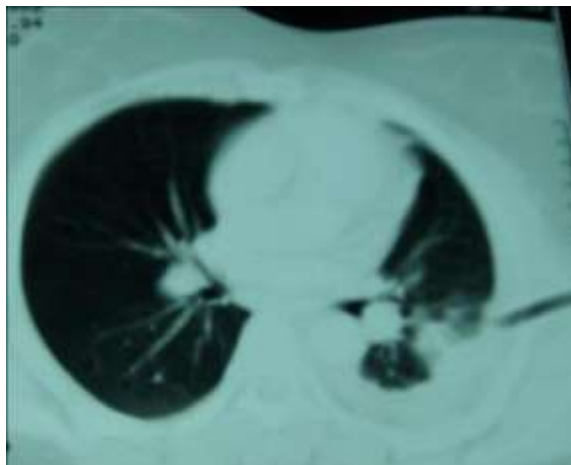
In the last 13 years, we have received and managed two cases of Echinococcal pneumothorax in Thoracic Surgery Department. Firstly, a 17 year old girl from Basrah, south

of Iraq admitted in July 1995 to a medical ward with sudden dyspnoea. Chest radiograph showed a left tension pneumothorax for which an apical chest tube was inserted. One month later, she was transferred to Thoracic Surgery Department because of persistent air leak, collapsed left lung and empyaema (Fig.1-A). CT scan of the chest (Fig.1-B] revealed similar findings. Left thoracotomy was done. The surprising finding was a laminated membrane of ruptured PHC floating in the pleural space. The membrane and pus were removed through washing of pleural cavity and bronchial air leaks were dealt with accordingly. Lung decortication was performed.

1A



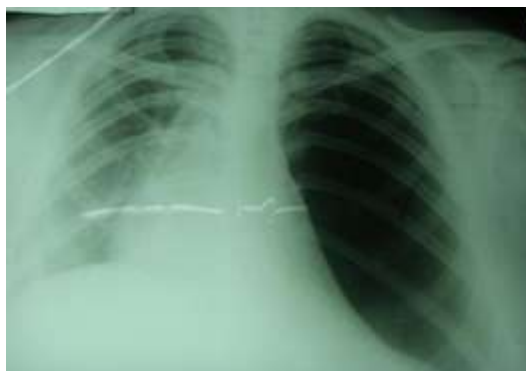1B



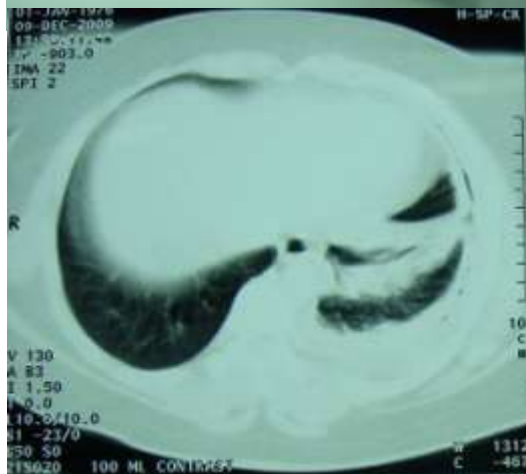
Secondly, a lady of 35 referred to the Department of Thoracic Surgery in December 2009 with a left chest tube placed in a district hospital one month earlier to drain a tension pneumothorax during pregnancy (Fig. 2-A). The cause of referral was persistent air leak, lung collapse and empyema. The lung failed to expand despite a second chest tube insertion and continuous suction.

Chest CT scan (Fig 2-B) showed a cavity in left lower lobe. Our policy is to operate for failure of lung expansion and persistent air leak after two weeks of conservative treatment. The patient had left thoracotomy with similar operative findings and procedure to case 1, though the cyst was in the left lower lobe.

2A



2B



In both cases, the postoperative period was uneventful. Thorough investigations were done but failed to discover hydatid cysts in other organs. On hospital discharge, Albendazole 10 mg/kg/day was prescribed for 3 months with an interval of 10 days between one month and another. During 13 years follow up, the first patient had no recurrence, though the second patient had a short follow up so far.

Discussion

Tension pneumothorax secondary to rupture of PHC is rare¹⁻⁵. There are sporadic case reports in countries like Turkey, Iraq, UK, Italy, India, Australia, Spain and Greece with nearly 50 cases reported since 1950¹⁻³. The clinical picture is dominated by pneumothorax and anaphylactic reaction¹. The pneumothorax can be of the tension type; the collapsed lung throwing the edges of the pericyst cavity into folds which act as a valve¹. The combination of massive pneumothorax and anaphylaxis may prove fatal¹⁻⁵.

The condition is almost always misdiagnosed as tuberculosis, due to the prevalence of tuberculosis in many areas of the world endemic to hydatid disease¹. Preoperative diagnosis is difficult; however, certain observations give hints. Beside residence in an endemic area, the drainage of crystal clear fluid, the presence of pieces of laminated membrane [plugging the

tube sometimes], the persistent air leak and features of anaphylaxis are helpful¹⁻³. The chest radiograph may show irregular gas-fluid level due to the laminated membrane floating in the pleural space⁴. Examination of pleural fluid for scolices may be positive¹. Eosinophilia may be a valuable pointer in the investigation of pleural effusions of doubtful origin if the source was a rupture of a pulmonary hydatid^{3,4}. Nothing short of thoracotomy can help these patients in the acute or chronic phase.

Our 2 patients presented to the primary care centre as a tension pneumothorax. Both came from rural areas endemic to hydatid disease but in both we lacked the description of the fluid drained by chest tubes. All the inquiries failed to show any anaphylactic response or allergic reaction. Thus, like other cases reported before, preoperative diagnosis could not be made.

Although rare, intra-pleural rupture of PHC should be considered in patients presenting with pneumothorax in areas endemic to pulmonary hydatidosis especially those with persistent air leak and failure of the lung to expand after conservative measures. Thoracotomy for extraction of the ruptured cysts is the only answer to deal with the infected space and closure of the bronchial leaks. Postoperative Albendazole is recommended to prevent recurrence.

References

1. Saidi F., Surgery of Hydatid Disease. W.B. Saunders Co. Ltd. London. 1976.
2. Bakir F and Al-Omeri M A. Echinococcal Tension Pneumothorax. Thorax. 1969; 24
3. S.J. Connelian, A.W. Jowett and R.S.E. Wilson. Hydatid Disease presenting as Tension Pneumothorax. Br. J. Dis. Chest (1979) 37, 405.
4. Kürkçüoğlu IC, Eroğlu A, Karaoğlanoğlu N, Polat P. Tension pneumothorax associated with hydatid cyst rupture. J Thoracic Imaging 2002 January; 17 (1): 78-80.
5. Erdal Yekeler, Onur Celik, and Cevdet Becerik. A Giant Ruptured Hydatid Cyst Causing Tension Pneumothorax and Hemothorax in a Patient with Blunt Thoracic Trauma: a Rare Case Encountered in the Emergency Clinic. The Journal of Emergency Medicine . Vol XX, No. X. pp XXX, 2009.
6. Waddle N. Pulmonary hydatid disease. A review of 478 cases reported in the Louis Barnett Hydatid Registry of the Royal Australasian College of Surgeons. Aust. N.Z.J. Surg. 1950, 19, 273.