

RECURRENT PILOMATRIXOMA

Abdulameer Muhsin Aldaraji

MB,ChB, FICMS, General Surgery, Al-Faiha General Hospital, Basrah, IRAQ

Abstract

Pilomatixoma is a rare tumor of the matrix cells of the hair follicle, it commonly occurs in young male patients and the commonest site is the head and neck region. Here is an odd case at which the tumor developed in the lower limb of a 65 year old male patient.

Introduction

Pilomatixoma, also known as calcifying epithelioma of Malherbe or pilomatricoma. It is a benign neoplasm that is derived from hair follicle matrix cells. These lesions are typically found in the head and neck region, but less commonly in the extremities¹⁻⁷. It occurs at 1st & 2nd decades of life, but can develop in old people. The lesion is usually less than 10 mm in diameter but a giant form can occur in rare cases. Recurrence after surgical excision is rare, but could occur especially in aggressive type^{8,9}.

Case Report

A 65 year old man presented with 6 months history of gradual onset of a painless left thigh mass. He denied any history of trauma and he had no fever, weight loss, fatigue, paraesthesia or any other associated symptoms. Physical examination showed a 10x10 cm, non-tender, firm mass over the anterolateral aspect of the middle of the left thigh. It was superficially attached to the skin but not attached to the deep structures and was easily mobile in all directions. It had smooth surface, well defined edge, and not pulsatile. The overlying skin was normal and there was no lymphadenopathy. The neurovascular

examination of the left lower limbs was normal.

Plain x-ray of the left thigh was normal apart from soft tissue shadow. Ultrasonic examination showed a well-defined solid mass at the subcutaneous tissue of the left thigh. Hematological & biochemical investigations were unremarkable.

Excision of the mass was done under local anesthesia and it was sent for histopathological examination.

Grossly, it was a nodular mass, 10x7x4 cm, covered by skin ellipse. The mass is white-yellow in color, hard, granular and gritty.

Microscopic examination reveals nests of basal cells with abundant abrupt keratinization forming ghost cells with no evidence of malignancy, the diagnosis was giant pilomatixoma (Figure 1).

After eight and a half month, the patient presented with a recurrent mass at the previous site of tumor, it was 5x5x2 cm. Excision was done with the overlying skin under local anesthesia (Figures 2-5). Histopathological examination showed aggressive pilomatixoma with cellular atypia with no malignancy. Postoperatively, the wound recovered well without any complications. He had no evidence of recurrence in his one-year follow-up.

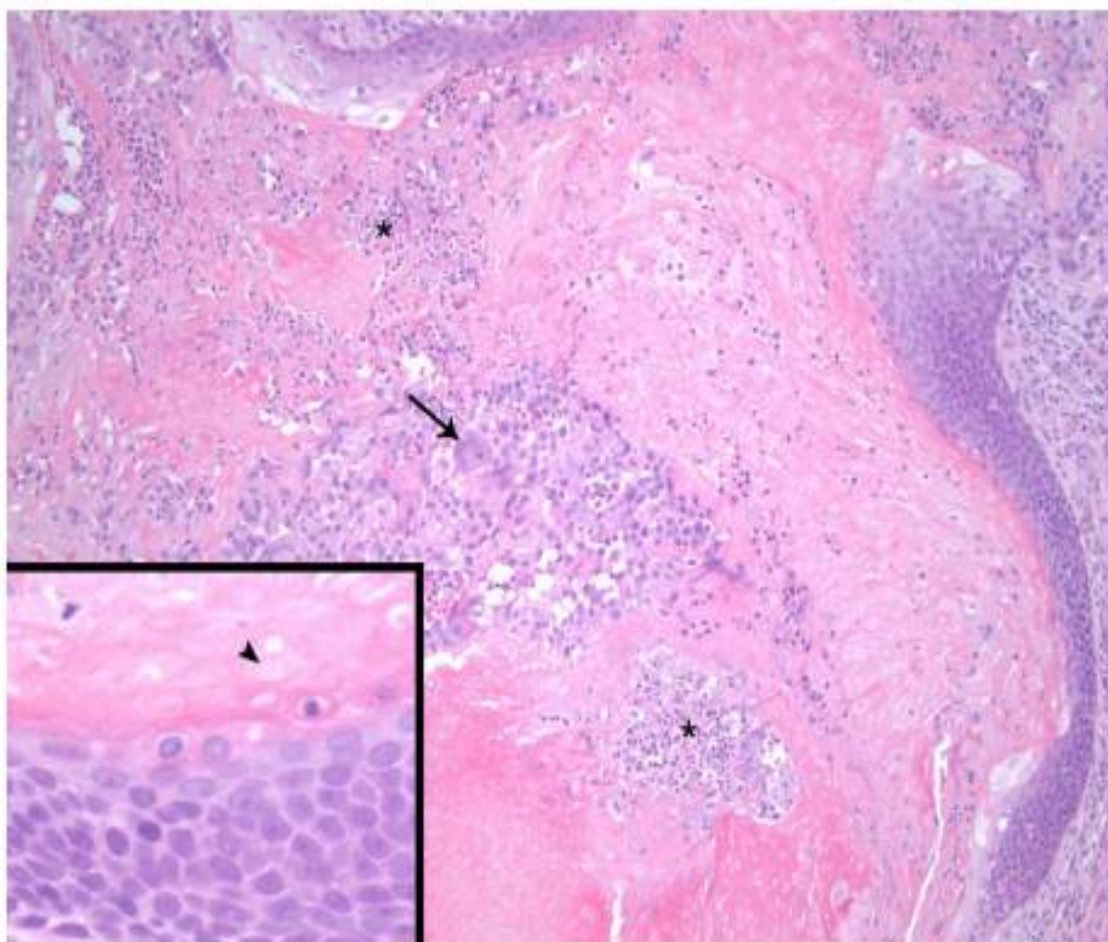


Figure 1: Pilomatrixoma of the left thigh

Asterisks: basaloid epithelium with acute inflammatory cells, Arrow: foreign body giant cells. Arrow head: Ghost cells characteristically retain their cell and nuclear borders, however, the nuclei lose their basophilic staining leaving a “ghost-like” remnant in eosinophilic keratin debris.

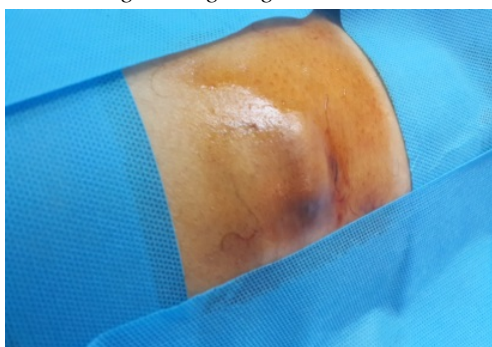

Figure 2: Recurrent mass

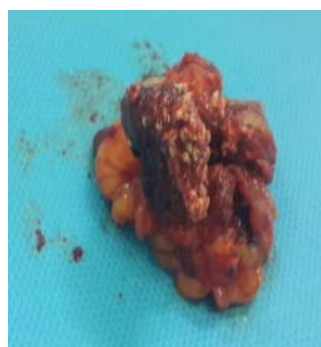

Figure 3: Excised tumor

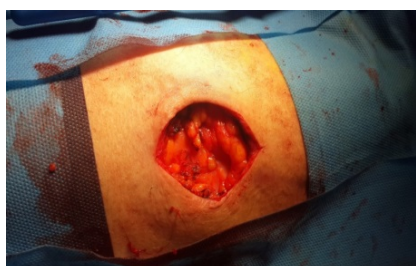

Figure 4: Skin defect after excision

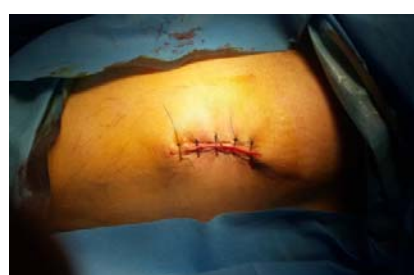

Figure 5: Wound closure

Discussion

In 1880, Malherbe and Chenantais first described this benign lesion and referred to as the calcifying epithelioma, though it was thought to derive from sebaceous glands¹⁰. The term pilomatrixoma was used in a publication by Forbis and Helwig in 1961 to better describe the histological source¹¹. These tumors are usually found in the head and neck region, but they have also been described in extremities. They present most commonly in children and young adults, and more in females^{12,13}.

A rare malignant form, pilomatrix carcinoma, has been described¹²⁻¹⁴, and about 90 cases have been reported in the literature. It is locally aggressive tumor and can recur. In several cases, it has demonstrated metastases. Many features are similar between these benign and malignant lesions; include a high mitotic rate with atypical mitoses, central necrosis, infiltration of the skin and soft

tissue, with invasion of blood and lymphatic vessels^{12,13}.

This patient was an adult male and presented with a lesion in the lower limb unlike the usual presentation of such lesions in children and young adult female patients. In addition, pilomatrixoma is a giant type (more than 5 cm) & aggressive recurrent disease unlike the common presentation of such lesions in small size (less than 3 cm). Recurrent aggressive disease is rare (0-3%)¹⁵⁻¹⁹. Recurrence may be due to incomplete excision^{8,9}. It is excised because of malignant potential of such lesions^{20,21}.

Pilomatrixomas are often misdiagnosed on preoperative evaluation. In a series of 51 pilomatrixomas, Wells et al found that the referring diagnosis was incorrect in 94% of cases²². Incorrect preoperative diagnoses most commonly included unidentified masses, as well as epidermoid cysts, sebaceous cysts, dermoid cysts, nonspecified cysts, and foreign bodies^{1,23}.

References

1. Kumaran N, Azmy A, Carachi R, Raine PA, Macfarlane JH, Howatson AG. Pilomatrixoma – accuracy of clinical diagnosis. *J Pediatr Surg.* 2006;41:1755–1758. [PubMed]
2. Marrogi AJ, Wick MR, Dehner LP. Pilomatric neoplasms in children and young adults. *Am J Dermatopathol.* 1992;14:87–94. [PubMed]
3. Migirov L, Fridman E, Talmi YP. Pilomatrixoma of the retroauricular area and arm. *J Pediatr Surg.* 2002;37:E20. [PubMed]
4. Schweitzer WJ, Goldin HM, Bronson DM, Brody PE. Solitary hard nodule on the forearm. Pilomatricoma. *Arch Dermatol.* 1989;125:828–829. [PubMed]
5. Meyer RS, Sanchez AA, Bannykh G, Donthineni-Rao R, Botte MJ. Forearm mass in a 31-year-old man. *Clin Orthop.* 2004;424:280–286. [PubMed]
6. Wagner AM. A 12-year-old girl with an enlarging nontender nodule on the arm. *Pediatr Ann.* 2006;35:445–447. [PubMed]
7. Yencha MW. Head and neck pilomatricoma in the pediatric age group: a retrospective study and literature review. *Int J Pediatr Otorhinolaryngol.* 2001;57:123–128. [PubMed]
8. Satoh M, Ookouchi M, Yamamoto T. Photoletter to the editor: Proliferating pilomatricoma with no recurrence during a 3-year follow-up. *J Dermatol Case Rep.* 2012;6:127–129. [PMC free article] [PubMed]
9. Sakai A, Maruyama Y, Hayashi A. Proliferating pilomatricoma: a subset of pilomatricoma. *J Plast Reconstr Aesthet Surg.* 2008;61:811–814. [PubMed]
10. Malherbe A, Chenantais J. Note sur 1' pitheliome calcifi des glandes sebacees. *Prog Med (Paris)* 1880;8:826-828[pubmed]
11. Forbis R, Jr, Helwig EB. Pilomatrixoma (calcifying epithelioma) *Arch Dermatol.* 1961;83:606–618. [PubMed]
12. Dutta R, Boadle R, Ng T. Pilomatrix carcinoma: case report and review of the literature. *Pathology.* 2001;33:248–251. [PubMed]
13. Mikhaeel NG, Spittle MF. Malignant pilomatrixoma with multiple local recurrences and distant metastases: a case report and review of the literature. *Clinical Oncology.* 2001;13:386–389. [PubMed]
14. H. P. Niedermeyer, K. Peris, and H. Höfler, "Pilomatrix carcinoma with multiple visceral metastases: report of a case," *Cancer*, vol. 77, no. 7, pp. 1311–1314, 1996. View at Publisher • View at Google Scholar • View at Scopus
15. F. W. Moehlenbeck, "Pilomatrixoma (calcifying epithelioma). A statistical study," *Archives of Dermatology*, vol. 108, no. 4, pp. 532–534, 1973. View at Publisher • View at Google Scholar • View at Scopus
16. C. T. Sasaki, A. Yue, and R. Enriques, "Giant calcifying epithelioma," *Archives of Otolaryngology*, vol. 102, no. 12, pp. 753–755, 1976. View at Google Scholar • View at Scopus
17. P. Solanki, I. Ramzy, N. Durr, and D. Henkes, "Pilomatrixoma. Cytologic features with differential diagnostic considerations," *Archives of Pathology and Laboratory Medicine*, vol. 111, no. 3, pp. 294–297, 1987. View at Google Scholar • View at Scopus
18. C. G. Julian and P. W. Bowers, "A clinical review of 209 pilomatricomas," *Journal of the American Academy of Dermatology*, vol. 39, no. 2, pp. 191–195, 1998. View at Publisher • View at Google Scholar • View at Scopus
19. M. Y. Lan, M. C. Lan, C. Y. Ho, W. Y. Li, and C. Z. Lin, "Pilomatricoma of the head and neck: a retrospective review of 179 cases," *Archives of Otolaryngology—Head and Neck Surgery*, vol. 129, no. 1 15.
20. Pant I, Joshi SC, Kaur G, Kumar G. Pilomatricoma as a diagnostic pitfall in clinical practice: report of two cases and review of literature. *Indian J Dermatol.* 2010;55:390–392. [PMC free article] [PubMed]
21. Sassmannshausen J, Chaffins M. Pilomatrix carcinoma: a report of a case arising from a previously excised pilomatrixoma and a review of the literature. *J Am Acad Dermatol.* 2001;44:358–361. [PubMed]
22. Wells NJ, Blair GK, Magee JF, Whiteman DM. Pilomatrixoma: A common, benign childhood skin tumor. *Can J Surg.* 1994;37:483–486. [PubMed]
23. Pirouzmanesh A, Reinisch JF, Gonzalez-Gomez I, Smith EM, Meara JG. Pilomatrixoma: A review of 346 cases. *Plast Reconstr Surg.* 2003;112:1784–1789. [PubMed]